

Lateral, Dense, Mega—Is This the Future?

Jerry Wong, MD Vancouver, BC, Canada

COLUMNS

- 2 President's Message
- 3 Co-Editors' Messages
- 5 Notes from the Editor Emeritus
- 20 From the Literature
- 21 Pioneer of the Month
- 22 Cyberspace Chat
- 25 Pearls from Providence
- 27 Letter to the Editor
- 28 Once Upon a Time
- 33 Surgical Assistants Corner
- 35 Classified Ads

FEATURE ARTICLES

- 7 Whorl on Scalp of Thai Monk and Nun
- 9 Solutions to Solving the Public's Perception of Hair Restoration
- 11 Facial Framing: "It's not all about the hair, it's about the eyes"! Utilizing Art and Mathematic Principles in Facial Framing and Hair Restoration Design
- 15 Irregular and Sinuous Anterior Hairline: Prior Technique Refinement and Male and Female Trace Parameters
- 17 The Psychological Impact of Hair Loss Can Be Alleviated
- 29 In Memory of Robert Thomas, MD, and Pierre Pouteaux, MD
- 35 Offering Financing Options Allows More Patients to Afford Surgery

The past 1–2 years have been pretty exciting for us. After seeing multiple cases of 4,000 FUs dense-packed using lateral slits, we're convinced that for patients with advanced hair loss (Norwood 5 or 6) these sessions are ideal. There has been a lot of very positive feedback from both patients and colleagues. Following is how we approach and do one of these megasessions.

As Figure 2 shows, perpendicular slits are cut perpendicular to the direction of hair flow with the blade handle slanted to match the existing hair angle. With this technique, the slits "sandwich" the grafted hair shaft to consistently maintain a much more acute angle during the healing process. The closer grafted hair matches existing hair the better it blends and thus the less detectable it becomes. The angulations and the resulting "shingling" effect will also provide improved coverage.



Figure 1. Pre-op and 8 months post-op side view of patient in mid-40s with 5,825 follicular.

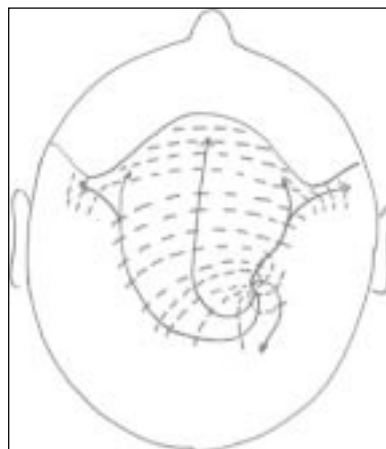


Figure 2. Figure showing hair direction and plane of incisions.

This procedure has been made possible by the following two technological advances:

1. *Dr. Limmer's microscopic slivering and graft dissections.* Since adopting this technique, our graft quality and graft count have both dramatically improved. In our clinic we have 20 cutting stations using the Mantis microscope.
2. A blade cutter making custom-sized razor recipient blades (Figure 3).

To minimize vascular and tissue damage we use only the chisel tip, and because these blades are so sharp there is no need to use the pointed tip. The chisel tip creates a more exact and shallow pocket for the grafts.

continued on page 18

See page 34 for
 information on
 booking your flights
 and hotel for Sydney.