

IN THIS ISSUE

Past Presidents Reflect on 30 Years of the ISHRS

Review of the 30th World Congress of the ISHRS

The “Punching-Out” Technique to Reduce the FUT Scar

Ito Meireles Filho, MD | Salvador, Bahia, Brazil | itomeireles@me.com; Henrique N. Radwanski, MD | Rio de Janeiro, Brazil

This paper was presented during the 30th World Congress of the ISHRS in Panama.

ABSTRACT

A widened scar from a previous strip-removal procedure (follicular unit transplant) is a commonly encountered complaint from patients coming in for a second hair restoration surgery. Options for addressing widened scars have included surgical scar revision, transplanting the scar with follicular units, and scalp micropigmentation. The authors present a new approach, where the scar may be thinned with a punching-out technique followed by resuturing the area. Advantages of the technique include that the time spent on this procedure is usually less than 10-15 minutes, it utilizes skills and equipment that most hair restoration surgeons already have, and it also does not use additional precious follicular units. Our experience using this technique in 58 patients showed improved appearance of the scar.

Keywords: follicular unit excision (FUE), follicular unit transplant (FUT), “punch-out” technique, scar revision

This article is open access and may not be copied, distributed, or modified without written permission from the International Society of Hair Restoration Surgery.

INTRODUCTION

Follicular unit transplantation (FUT) by the strip technique is an established procedure that is still widely used in the correction of androgenetic baldness in Brazil and worldwide. In its execution, it is necessary to resect an ellipse of scalp skin from the donor area to obtain the follicular units (FUs), resulting in a scar, which is usually well hidden under the hairs in the occipital and temporal region. The widening of these scars is the most common complaint related to the FUT technique, corresponding to up to 25% of the complications found (Figure 1).¹

This paper describes a relatively fast and practical scar revision technique in which follicular unit excision (FUE) is used with a “punch out” technique. The senior author shares his experience using this “punch out” FUE technique to revise unsightly FUT scars with excellent aesthetic results in 58 patients.

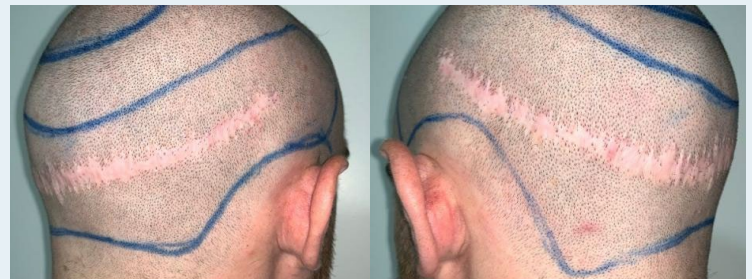METHOD & MATERIALS

When carrying out hair transplantation using the FUE technique, the extraction of the FUs is performed with a punch. The punch removes a circular segment of skin with a thickness that often varies between 0.8 and 1.0mm. The power of skin contraction observed in the remodeling phase leads to the complete closure of these orifices in the first 24-48 hours.

By the same principle, we imagined that in a widened scar, we could remove a large amount of scar tissue using the same punch and achieve a natural reduction in the width of the scar. We began using FUE punches in FUT scars to determine if this method was effective.

In the first cases, we allowed healing to occur naturally and observed an improvement in scar appear-

FIGURE 1. Enlarged scar



PLAN TO ATTEND!



31ST WORLD CONGRESS
NOVEMBER 1-4, 2023



ance and texture. We also noted the emergence of hairs that were probably trapped in the scars that were released by the orifices made with the punches. However, the reduction in width was not as significant as expected, especially in cases of scar width greater than 5mm. Based on these findings, after creating the holes with FUE punches, we began running a continuous suture along the entire length of the scar and observed a significant reduction in the width of the scars and excellent aesthetic results with this technique.

We used the following materials:

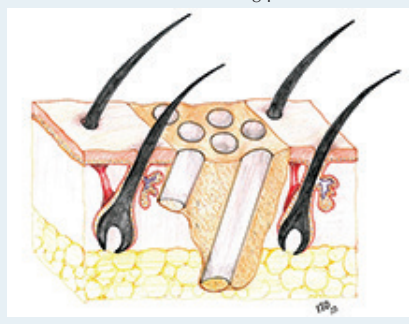
- CAP IV electric rotor
- Serrated sharp punch of 0.8 and 1.0mm
- Mononylon 5.0 suture
- Kelly tweezers
- 3ml syringe
- Hypodermic needle
- Anesthetic solution: Saline solution 0.9%, 100mL; epinephrine, 0.5mL; ropivacaine 10%, 10mL; lidocaine 2%, 10mL

Typically, patient scalps are shaved when undergoing hair transplantation. In those undergoing scar revision alone, the procedure can be done without shaving the scalp. After appropriately cleansing the area, a tumescent infiltration of the entire scar with the anesthetic solution is done, allowing 15 minutes for vasoconstriction and scalp analgesia.

We start the procedure with alternating punctures along the entire length of the scar in order to remove the greatest amount of scar tissue, preserve the scar skin bridges, and avoid discontinuity between the margins. Punctures are performed at an angle of 45 degrees in relation to the skin to preserve possible FUs in the margins and increase the amount of tissue removed. We press the punch deeply until the scar offers no more resistance. The depth varies according to the thickness of the scar. The punch of choice is the serrated punch with a length of 5mm and a diameter of 0.8mm for scars up to 5mm wide and 10mm for scars wider than 5 mm.

The holes are created in an alternating pattern, to create

FIGURE 2. Holes in alternating pattern



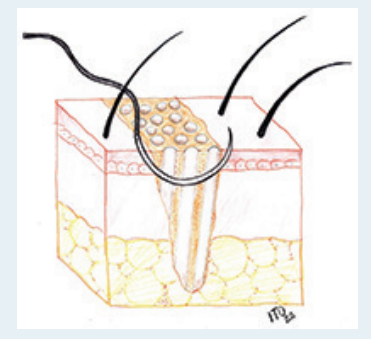
an irregular pattern of contraction, break the continuous scarring pattern, and reinforce the naturalness of the result (Figure 2). We remove the remaining scar debris from the holes with Kelly forceps to completely free the punctured spaces.

We then perform a continuous skin suture with Mononylon 5.0 thread to approximate the spaces in the scar and thus reduce the scar width (Figure 3). Some tension should be applied to the suturing to ensure closure of the punch holes.

It is important to point out that we do not perform imbrication of the scar to avoid burial of the skin and subsequent cyst formation. We only perform superficial approximation allowing the subcutaneous tissue to carry out spontaneous organization.

The average surgical time for revision of the entire scar is around 15 minutes, and we can perform it simultaneously with the removal of FUs or implantation of the vertex (crown area) when performed together with hair restoration surgery without interfering with the duration of the surgery.

FIGURE 3. Continuous suture



POST-OPERATIVE CARE

There is no need for dressings. We recommend daily washing of the scar with water and antiseptic soap. The stitches are removed after seven days post-surgery, and we encourage daily massage of the scar with almond oil after this period.

If the scar revision is performed along with hair restoration surgery, the post-operative medications follow the standard hair transplant protocol adopted by our surgical team: oral cefadroxil 500mg every 12 hours for five days and ketoprofen 100mg every 12 hours for three days.

If only scar “punch-out” technique is performed, we only recommend oral ketoprofen 100mg every 12 hours for three days for any discomfort. Antibiotic therapy is not necessary.

DISCUSSION

Patient preference for the FUE technique has increased due to the avoidance of a linear scar and a faster recovery period. However, FUT is still commonly performed today and has its own advantages. Thus, hair restoration surgeons will continue to frequently encounter patients with a linear scar in the donor area from prior FUT surgery. It is important that they be familiar with the treatment options and their advantages and disadvantages for improving scar appearance from prior FUT procedures so that they can counsel their patients appropriately.

Current methods for improving the appearance of prior FUT scars and their advantages and disadvantages include:

- *Traditional resection of the entire scar:* The scar is removed and then closed with suture, usually in two planes. This procedure is similar in concept to the original FUT strip removal. As the cause of the widening of the incision is often the tension provided by the lack of elasticity of the scalp, there is a natural risk for repeated increased tension and widened scar recurrence. Post-operative pain can be a limiting factor in some patients.
- *Implantation of FUs into the scar line:* This method can often be effective in increasing hair density in the scar and decreasing the visibility of the scar. It does not remove scar tissue or soften the scar. Additionally, this method usually consumes many FUs that may be needed to address the underlying hair loss.
- *Micropigmentation:* This is a minimally invasive procedure that uses pigment deposition in the scalp for semi-permanent scalp camouflage. This reduces the appearance and visibility of the scar tissue. However, it does not increase hair density over the scar, remove scar tissue, soften the scar, or reduce the width of the

scar. Micropigmentation may become undesirable in patients who develop white hair.²⁻⁴

Advantages of the “punch out” technique:

- It is relatively easy to execute.
- It is low cost.
- It does not require special materials or surgical training.
- It does not require hemostasis.
- It can be performed simultaneously with the extraction or implantation of FUs without interfering with the planned surgical time.
- There is relatively little pain in the post-operative period.
- The reduction of scar tissue and decreased adhesion of scar tissue to deeper tissue improves the tactile sensation of the scar.
- It offers improved aesthetic appearance of the scar.
- The narrowing of the scar allows more FU removal from above the scar (whereas a wider scar will cause the surgeon to be more cautious in removing follicles from above the scar to decrease the “curtain effect”).

As far as disadvantages of the “punch out” technique, so far, we have not observed difficulties or complications that represent a significant disadvantage for the technique employed. As this is a new study with a low sample size, more follow-up time is needed in order to record late complications, such as scarring hypertrophies, which were not observed at the time of publication.

CONCLUSION

Our experience using this technique in 58 patients showed an overall improved appearance of thinning, less depression, and decreased visibility of scar tissue. The following images show these results.

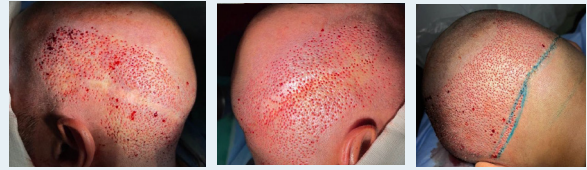Our unique FUE “punching-out” technique is relatively simple and easy-to-perform for the revision of widened scars from previous strip surgery. This technique should be added to a hair restoration surgeon’s arsenal in scar revision treatment options. Although more cases with longer follow-up are still needed, in our experience thus far, this technique is effective, has few disadvantages, and offers a high level of patient satisfaction.

References

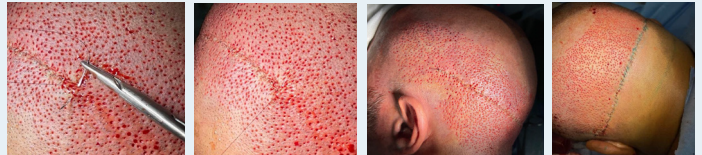1. Salanitri S, et al. Surgical Complications in Hair Transplantation: A Series of 533 Procedures. *Aesthetic Surg.* 2009;29(1):72-76.
2. Barrera A, Uebel CO. Transplante Capilar – A Arte do Microenxerto e Minienxerto de Unidade Folicular. 2a Edição- Rio de Janeiro. Revinter, 2015. *Complicações da área doadora.* 278-282.
3. Radwanski H., Ruston A., Gomes de Lemos R. Transplante Capilar: Arte e Técnica/ Organizadores. São Paulo: Roca, 2011. *Complicações da área doadora.* 286-287.
4. Carreirão S., Lessa S. New technique for closing punch graft donor sites. *Plast Reconstr Surg.* 1978;1(3):455-456. ■

SURGICAL SEQUENCE

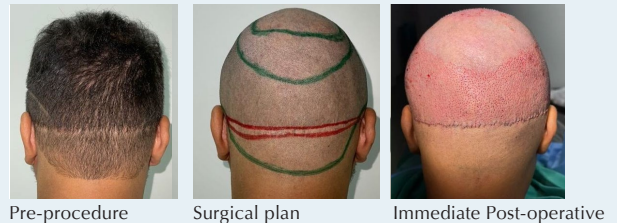
Step 1. Harvest follicular units from donor area (if applicable) and perform punch-out technique through scar.



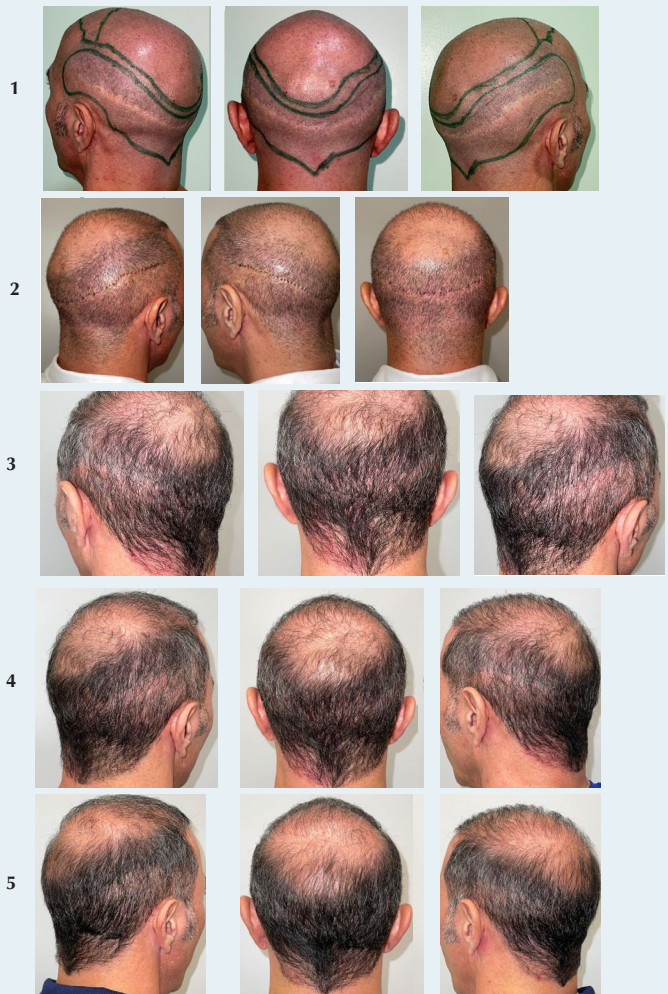Step 2. Suture the scar to close the punch holes.



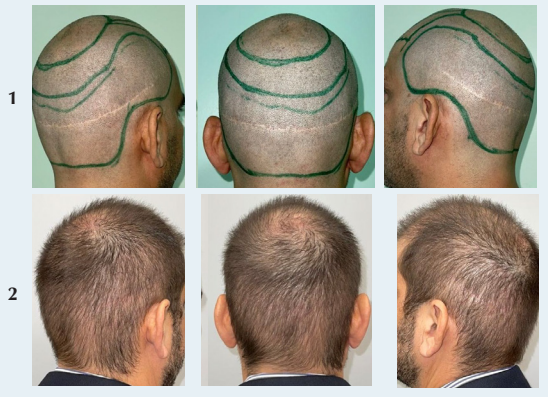Results



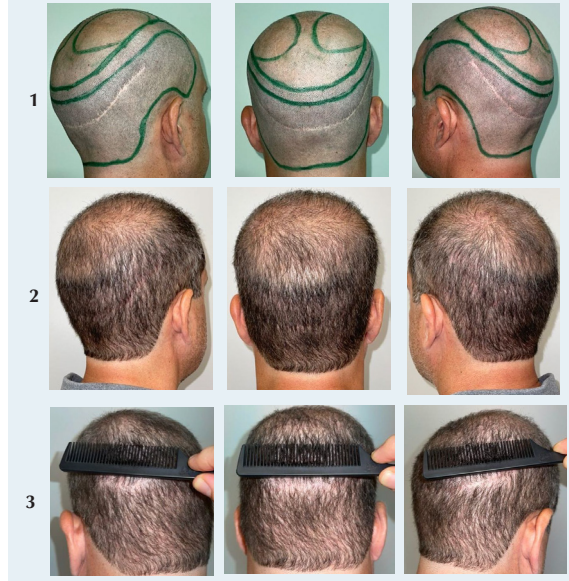CASE 1. **Row 1:** pre-operative. **Row 2:** post-operative day 8. **Row 3:** post-operative day 30. **Row 4:** post-operative day 60. **Row 5:** post-operative day 90.



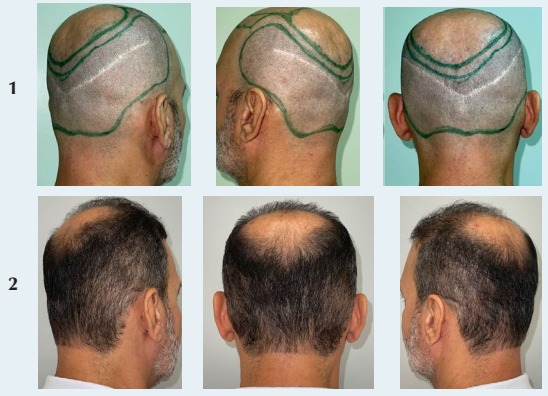CASE 2. Row 1: pre-operative. Row 2: post-operative day 45.



CASE 4. Row 1: pre-operative. Rows 2 & 3: post-operative day 60.



Case 3. Row 1: pre-operative. Row 2: post-operative day 60.



New WAW DUO FUE System



- Wireless + Wired Control
- Multiple Phases and Modes
- Flexibility of movement
- Surgery report with Graft Counting
- Simple Dismantle & Autoclave

New Hybrid Tornado Punch



The serrated hybrid tornado punch offers the advantages of a blunt and sharp punch combined in one.

- Transection Rate as low as <5%*
- Less Missing Grafts
- Chubby and Healthy Grafts

Contact us for more information on our products and for orders:



+32 (0)28807064
info@devroyeinstruments.com

*Based on user