



COLUMNS

- 74 President's Message
- 75 Co-editors' Messages
- 77 Editor Emeritus
- 83 Hair Sciences: An interview with Professor Michael Hamblin
- 90 Cyberspace Chat
- 92 How I Do It: How to place 1,500 grafts per hour using Choi implanters
- 95 Message from Paul J. McAndrews, Program Chair of the 2010 Annual Meeting
- 97 Surgeon of the Month: Frank Neidel, MD
- 98 Review of the Literature
- 100 Letters to the Editors
- 105 Surgical Assistants Editor's Message
- 106 Classified Ads

FEATURE ARTICLES

- 81 The slanticle
- 86 Review of the 16th Annual Orlando Live Surgery Workshop
- 93 Review of the Cowgirl Female Hair Loss Workshop
- 105 "Placing" strategies: Part 1

Different options in revision surgical hair restoration

Jeffrey S. Epstein, MD *Miami, Florida* jsemd@fhrps.com

Introduction

For patients with less than desirable aesthetic hairlines from prior hair transplantation, the most common recommended method for repair is further grafting. The concept is that the additional grafts that are theoretically performed in a more refined approach will conceal the old grafts. This approach can be quite useful, especially when the transplanted hairline as it presents is sufficiently high enough to allow for at least 10–15mm of further advancing with new grafting, and there is sufficient donor hair grafts. I have utilized this grafting technique in the great majority of the more than 1,500 revision procedures I have performed over the past 15-plus years, with very good to rather impressive outcomes in the large majority. In approximately half of these grafting cases, a small number of the most unaesthetic grafts (anywhere from 20 to as many as 50 or so) also need to be removed to achieve a more natural appearance, especially for those along the frontal-most hairline that are very noticeable due to size (3 or more hairs), angulation (too perpendicular), pitting of the surrounding skin, or poor location (placed too far forward and/or surrounded by scarring such as pitting or hypopigmentation).

There are certain circumstances, however, when further grafting is not the simple solution to the problem. As effective as this technique can be in many patients, in others it simply is not going to improve hairline aesthetics sufficiently to allow the patient to regain the natural look he greatly wants. This is particularly true in those patients with several aesthetic problems that include:

- hairlines that are too low or too flat (rounded instead of receded frontotemporal recessions);
- a large number of unnatural appearing grafts that cannot be concealed with further grafting; whether because of poor angulation, large size, or other aesthetic issues; and
- scarring of the surrounding skin from the prior placed grafts or from well-intentioned but unsuccessful efforts to improve appearances by graft removal and/or further grafting.

It is in these patients that one of the following three alternative procedures can and should be offered:

1. Linear excision of the entire or portion of the hairline.
2. FUE punch removal of prior placed hairline grafts.
3. Fusiform-shaped scalp reduction performed just behind the hairline.

One particular motivation for writing this article is to demonstrate the proper method and applications of these techniques. I do not take credit for inventing these techniques, for I have learned the basics of them from some of my more respected colleagues (such as Drs. Dow Stough and Shelly Kabaker), but I have modified them to allow them to achieve the most impressive results. Performed properly, these techniques have made a huge difference in the lives of some of my patients, allowing them to no longer need to continually worry about their unnatural appearance.

Linear Excision of the Hairline—Partial and Complete

Almost 11 years ago, I was faced with a very challenging case of a male who 20 years earlier underwent a series of plug and minigraft transplanting to create a 2.5cm-wide hairline that unfortunately was too flat and too far forward—just 7cm above the nasion. Another surgeon had attempted to remove some of the larger of the 700 or so grafts that contained 3–7 hairs each, which resulted in unaesthetic hypopigmented scarring in place of the grafts. The patient was resigned to wearing a hairpiece, unless something heroic was performed for him.

Plan to Attend



Hair Transplant Forum International Volume 20, Number 3

Hair Transplant Forum International is published bi-monthly by the International Society of Hair Restoration Surgery, 303 West State Street, Geneva, IL 60134. First class postage paid at Chicago, IL and additional mailing offices. POSTMASTER: Send address changes to Hair Transplant Forum International, International Society of Hair Restoration Surgery, 303 West State Street, Geneva, IL 60134. Telephone: 630-262-5399, U.S. Domestic Toll Free: 800-444-2737; Fax: 630-262-1520.

President: Edwin S. Epstein, MD

Executive Director: Victoria Ceh, MPA

Editors: Francisco Jimenez, MD
jimenezeditor@clinicadelpelo.com
Bernard P. Nusbaum, MD
dmusbaum@yahoo.com

Managing Editor, Graphic Design, & Advertising Sales:
Cheryl Duckler, 262-643-4212
cduckler@yahoo.com

Scientific Section: Nilofer P. Farjo, MBChB

Surgeon of the Month: Samuel M. Lam, MD;
Maurice P. Collins, MBChB

Cyberspace Chat: Sharon A. Keene, MD

The Dissector: Russell Knudsen, MBBS

How I Do It: Bertram Ng, MBBS

Hair's the Question: Sara M. Wasserbauer, MD

Surgical Assistants Corner Editor:
Laurie Gorham, RN
laurieg@bosley.com

Basic Science: Satoshi Itami, MD
Andrew Messenger, MBBS, MD
Ralf Paus, MD
Mike Philpott, PhD
Valerie A. Randall, PhD
Rodney Sinclair, MBBS
David Whiting, MD

International Sections:

Asia: Sungjoo Tommy Hwang, MD, PhD
Australia: Jennifer H. Martinick, MBBS
Europe: Fabio Rinaldi, MD
South America: Marcelo Pitchon, MD

Review of Literature:

Dermatology: Marc R. Avram, MD
Nicole E. Rogers, MD
Plastic Surgery: Sheldon S. Kabaker, MD

Copyright © 2010 by the International Society of Hair Restoration Surgery, 303 West State Street, Geneva, IL 60134. Printed in the USA.

The views expressed herein are those of the individual author and are not necessarily those of the International Society of Hair Restoration Surgery (ISHRS), its officers, directors, or staff. Information included herein is not medical advice and is not intended to replace the considered judgment of a practitioner with respect to particular patients, procedures, or practices. All authors have been asked to disclose any and all interests they have in an instrument, pharmaceutical, cosmeceutical, or similar device referenced in, or otherwise potentially impacted by, an article. ISHRS makes no attempt to validate the sufficiency of such disclosures and makes no warranty, guarantee, or other representation, express or implied, with respect to the accuracy or sufficiency of any information provided. To the extent permissible under applicable laws, ISHRS specifically disclaims responsibility for any injury and/or damage to persons or property as a result of an author's statements or materials or the use or operation of any ideas, instructions, procedures, products, methods, or dosages contained herein. Moreover, the publication of an advertisement does not constitute on the part of ISHRS a guaranty or endorsement of the quality or value of the advertised product or service or of any of the representations or claims made by the advertiser.

Hair Transplant Forum International is a privately published newsletter of the International Society of Hair Restoration Surgery. Its contents are solely the opinions of the authors and are not formally "peer reviewed" before publication. To facilitate the free exchange of information, a less stringent standard is employed to evaluate the scientific accuracy of the letters and articles published in the Forum. The standard of proof required for letters and articles is not to be compared with that of formal medical journals. The newsletter was designed to be and continues to be a printed forum where specialists and beginners in hair restoration techniques can exchange thoughts, experiences, opinions, and pilot studies on all matters relating to hair restoration. The contents of this publication are not to be quoted without the above disclaimer.

The material published in the Forum is copyrighted and may not be utilized in any form without the express written consent of the Editor(s).

President's Message

Edwin S. Epstein, MD Virginia Beach, Virginia esehairmd@gmail.com

At the last strategic planning meeting, the Board of Governors suggested that the ISHRS be proactive with respect to emerging, new technologies, both in its position as well as in educational programs. Such technologies include mechanized or robotic follicle extraction, hair growth factors, and cell biology. The recently passed health care legislation in the United States points to a direction of more government regulation and intervention. Already many medical societies have begun to establish "best practice guidelines." Most of these guidelines are derived from evidence-based medical studies and data, and many can be found at www.guideline.gov/, which is the U.S. National Guidelines Clearinghouse, an initiative of the Agency for Healthcare Research and Quality. The ISHRS CME Committee will soon begin the process of establishing common, best practices based on polling experts in our field.

Over the years, hair restoration surgery has evolved into a team effort, using highly skilled and trained surgical technicians to assist the doctor in graft preparation and placement. I am concerned by recent trends of allowing non-physician staff to have a greater involvement in graft harvesting using various automated follicular extraction devices. This procedure is essentially a mini scalp biopsy, and it is still considered a minor surgical procedure by most malpractice insurance carriers. While state and international regulations may vary on the interpretation as to how wide the physician umbrella is in regards to delegation of responsibility, in my opinion, we must be very careful, as a society, not to relinquish control in this area.

New technology companies are currently, and may in the future, market directly to physicians not currently performing hair restoration surgery. This is common practice in other areas of cosmetic surgery such as weekend laser and filler courses. There is also the potential for entrepreneur non-physicians, trained in hair transplant techniques, to offer their services to physicians, who could potentially never participate in the procedure, except to draw a hairline. The results of early hair transplant techniques (i.e., "plugs") are still ingrained in the psyche of the public, despite the efforts of the ISHRS and its members to reverse this perception using state-of-the-art techniques. I am concerned that progress in this direction may be set back by a new wave of procedures performed by sub-optimally trained physicians.

As government regulation of medicine increases, best practice guidelines will have more importance and relevance. The development of best practice guidelines is a big challenge: It requires a huge effort by the Committee, and a complete response from those members surveyed. It may also shape the direction of our field.

In addition to the "experts" being surveyed, the CME Committee will also poll the entire membership to determine current practices. The two sets of data—that is, best practices and current practices—will be analyzed and compared to determine the resultant gap. As suggested by AACME's new methodology, the CME Committee will then develop educational programs (annual meeting sessions, webinars, regional workshops) with the goal to close the identified gap. I encourage all of you to complete these surveys. There will be a series of approximately 10 surveys, each on various aspects of hair restoration surgery, that will be conducted over the course of 2 years. The first survey will debut at the Boston annual meeting utilizing the audience response system (ARS) technology. You will be able to see the results in real-time, which I am sure will be interesting to all of us in the field.

Edwin S. Epstein, MD



Co-editors' Messages

Paco Jimenez, MD *Las Palmas, Spain*
jimenezeditor@clinicadelpelo.com



I have been recently reading the seminal papers on human hair transplantation that the visionary Dr. Shoji Okuda published in 1939, and one of his histological descriptions that caught my attention was the “proliferation of the perifollicular connective tissue (donor dermal sheath)...with projections into the surrounding connective tissue” occurring as early as 7 days post-transplantation. For many years, this perifollicular mesenchymal component, known as the dermal or connective tissue sheath, has been almost completely neglected. However, it appears that now is the time to restore its reputation, as there are numerous publications appearing in the literature on this topic. Why is it that the dermal sheath is now so attractive to basic researchers? Because there is substantial evidence indicating that it might be the principal niche for cutaneous mesenchymal stem cells (MSCs).

Unfortunately, unlike the human bulge epithelial stem cells, which can be easily visualized in histologic tissue sections with the immunohistochemical marker CK15, we still don't have a reliable and easily detectable marker for the MSCs, although the neural stem cell marker nestin seems to be one of the best placed candidates.

There are a few clinical facts that may give you a hint of the importance of the dermal sheath:

1. These dermal sheath MSCs have multipotent capacity, capable of developing into smooth muscle cells, adipocytes, osteocytes, glial cells, and even neurons.

⇒ page 76

Bernard Nusbaum, MD *Coral Gables, Florida*
drnusbaum@yahoo.com



It seems that, within our ranks, the original skeptics of low level laser therapy (LLLT) (including myself) are gradually jumping the fence and recognizing that there may be, in fact, a beneficial effect on hair growth. In this issue we hope you will read with interest the interview with renowned laser scientist, Professor Michael Hamblin, former Featured Speaker of our Amsterdam ISHRS Annual Meeting. Dr. Hamblin cites a study (Shukla, et al.) in which the helium-neon laser induced anagen follicles in a mouse model. In humans, we have only one published double-blind, controlled study measuring hair growth in patients with androgenetic alopecia (Leavitt, et al.). Hair counts were shown to increase in a statistically significant manner during a 26-week treatment period. Many questions, however, still remain.

How do the LLLT units designed for home use compare in effectiveness to the “hood” office-based devices? Obviously, the latter carry a much higher price tag to the patients. How does LLLT complement other established therapies for androgenetic alopecia such as minoxidil and finasteride? If, as Dr. Hamblin suggests, LLLT possibly acts partially via ATP-sensitive potassium channels (as is postulated with minoxidil), then would it make sense to use both treatments together or might they in fact work by the same mechanism and therefore not produce additive effects? What is the optimum treatment dosage and frequency for LLLT and, as Dr. Hamblin mentions, could overexposure reverse the therapeutic benefits? What is the role, if any, for LLLT in

⇒ page 76

Editorial Guidelines for Submission and Acceptance of Articles for the *Forum* Publication:

1. Articles should be written with the intent of sharing scientific information with the purpose of progressing the art and science of hair restoration and benefiting patient outcomes.
2. If results are presented, the medical regimen or surgical techniques that were used to obtain the results should be disclosed in detail.
3. Articles submitted with the sole purpose of promotion or marketing will not be accepted.
4. Authors should acknowledge all funding sources that supported their work as well as any relevant corporate affiliation.
5. Trademarked names should not be used to refer to devices or techniques, when possible.
6. Although we encourage submission of articles that may only contain the author's opinion for the purpose of stimulating thought, the editors may present such articles to colleagues who are experts in the particular area in question, for the purpose of obtaining rebuttal opinions to be published alongside the original article. Occasionally, a manuscript might be sent to an external reviewer, who will judge the manuscript in a blinded fashion to make recommendations about its acceptance, further revision, or rejection.
7. Once the manuscript is accepted, it will be published as soon as possible, depending on space availability.
8. All manuscripts should be submitted to both drnusbaum@yahoo.com and jimenezeditor@clinicadelpelo.com.
9. A completed Author Authorization and Release form—sent as a Word document (not a fax)—must accompany your submission. The form can be obtained in the Members Only section of the Society website at www.ishrs.org.
10. All photos and figures referred to in your article should be sent as separate attachments in JPEG or TIFF format. Be sure to attach your files to the email. Do **NOT** embed your files in the email or in the document itself (other than to show placement within the article).

Submission deadlines:

June 5 for July/August 2010 issue

August 5 for September/October 2010 issue

October 5 for November/December 2010 issue

Dr. Jimenez's Message

from page 75

2. The inductive capacity: In the classic paper by Reynolds and Jahoda in *Nature* 1999, dermal sheath cells transplanted between human subjects of different sexes were capable of inducing new hair follicles.
3. The dermal sheath appears to play a key role in the mechanism of wound healing.
4. Mutations of the dermal sheath MSCs might be the underlying basis of mesenchymal skin neoplasms. In fact, several authors have proposed that the always scary dermatofibrosarcoma protuberans may represent a tumour of dermal sheath MSCs (Sellheyer, K.,

and D. Kahl. Cutaneous mesenchymal stem cells: status of current knowledge, implications for dermatopathology. *J Cut Pathol*. Epub ahead of print).

So, because the hair follicle appears to be the main repository of the epithelial and mesenchymal stem cells of the skin, is it just some sort of patriotic loyalty that makes me, a doctor working on a daily basis with hair follicles, say that our ally the follicular unit (a follicular-sebaceous-arrector pili muscle-sweat gland conglomerate) is the fundamental structure in skin homeostasis?

Paco Jimenez, MD

Dr. Nusbaum's Message

from page 75

other non-scarring alopecias such as alopecia areata and chemotherapy-induced alopecia?

Finally, we need to perform studies with long-term follow-up of patients receiving LLLT for androgenetic alopecia (AGA) and female pattern hair loss to confirm previous results and to determine if therapeutic benefits can be maintained with prolonged therapy.

Bernard Nusbaum, MD

Ellis

Instruments, Inc.

**State-of-the-art
instrumentation for hair
restoration surgery!**

For more information, contact:

**21 Cook Avenue
Madison, New Jersey 07940 USA
Phone: 800-218-9082 • 973-593-9222
Fax: 973-593-9277
E-mail: cellis@nac.net
www.ellisinstruments.com**

2009–10 Chairs of Committees

2010 Annual Scientific Meeting Committee: Paul J. McAndrews, MD
American Medical Association (AMA) House of Delegates (HOD) and Specialty & Service Society (SSS) Representative: Carlos J. Puig, DO (Delegate)

Annual Giving Fund Chair: Matt L. Leavitt, DO

Audit Committee: Robert H. True, MD, MPH

Bylaws and Ethics Committee: Robert T. Leonard, Jr., DO

CME Committee: Paul C. Cotterill, MD

Core Curriculum Committee: Edwin S. Epstein, MD

Fellowship Training Committee: Nilofer P. Farjo, MBChB

Finance Committee: Carlos J. Puig, DO

Hair Foundation Liaison: E. Antonio Mangubat, MD

Live Surgery Workshop Committee: Matt L. Leavitt, DO

Media Relations Committee: Robert T. Leonard, Jr., DO

Membership Committee: Marc A. Pomerantz, MD

Nominating Committee: Jennifer H. Martinick, MBBS

Past-Presidents Committee: Bessam K. Farjo, MBChB

Pro Bono Committee: David Perez-Meza MD

Scientific Research, Grants, & Awards Committee:

Michael L. Beehner, MD

Surgical Assistants Executive Committee: Laureen Gorham, RN

Surgical Assistants Awards Committee: Cheryl J. Pomerantz, RN

Task Force on Hair Transplant CPT Codes: Robert S. Haber, MD

Website Committee: Cam Simmons, MD

Ad Hoc Committee on Database of Transplantation Results on Patients with Cicatricial Alopecia: Nina Otberg, MD

Ad Hoc Committee on Regulatory Issues: Paul T. Rose, MD, JD

Evidence Based Medicine (EBM) Task Force: Sharon A. Keene, MD

Strategic Task Force (#3) on Increasing Physician Membership:

Edwin S. Epstein, MD

Strategic Task Force (#5) on Resources for Training Assistants:

Jennifer H. Martinick, MBBS

2009–10 Board of Governors

President: Edwin S. Epstein, MD *

Vice President: Jerry E. Cooley, MD*

Secretary: Jennifer H. Martinick, MBBS*

Treasurer: Carlos J. Puig, DO*

Immediate Past-President: William M. Parsley, MD*

Michael L. Beehner, MD

Vincenzo Gambino, MD

John D. N. Gillespie, MD

Alex Ginzburg, MD

Robert S. Haber, MD

Sharon A. Keene, MD

Jerzy R. Kolasinski, MD, PhD

Robert T. Leonard, Jr., DO

Bernard P. Nusbaum, MD

Arthur Tykocinski, MD

Surgical Assistants Representative:

Emina Karamanovski

*Executive Committee

Notes from the Editor Emeritus

Dow B. Stough, MD *Hot Springs, Arkansas* dbs4@cablelynx.com



The Holy Grail—automating the FUE process

Have we attained the Holy Grail? Is there a single device that can both extract FUEs and then implant them with the same precision (or better) than the experienced surgeon? Not Yet. However, there are a number of devices that can extract FUEs and one manufacturer that claims to be

able to plant them. A moment of applause is in order. This is indeed a spectacular accomplishment; much like the invention of the telegraph launched the industry that now allows us instant communication with anyone anywhere. WOW! And just as the telegraph was awe-inspiring at its invention, this technology is awe-inspiring, and thrilling.

There are now several companies who have the technology to remove FUEs with reported transection rates less than that achieved with manual FUE extraction. This has not been verified with any independent, unbiased clinical trials, but there are surgeons who believe the technology can do as promised. The basic technology utilizes either a blunt or sharp dissection tip that rotates to penetrate the skin and then applies suction to remove the FUE. The FUEs are then stored in a catch chamber until they are removed by the surgeon or implanted into the area desired. (This author encourages you to explore the different resources on the Internet to watch videos of the procedure and see just how fascinating this process is). I have yet to communicate with any surgeon using the implantation method as they feel it is still easier to plant the FUEs by hand than to use the device. There are reports from one company of 6,000 completed cases, lots of pictures of great outcomes with very minor scarring. Really? There are no IRB-approved, independently overseen clinical trials to verify the ease of use, ability of surgeon to learn the technique, and, most importantly, the rate of viability of the FUEs extracted and then implanted. The oversight is a major stumbling block for this technology. Just as with any emerging technology, independent verification of the efficacy of the procedure, the safety of the procedure, and, ultimately, the final outcomes of the procedure should be validated by someone other than the sponsor or beneficiary of the technology.

Another area of concern with the automation of the FUE transplantation is the temptation to train technicians (non-physician) and allow them to be the primary provider for the FUE transplant. There have been reports that this temptation has overshadowed the reality that whether a hair transplant is done with a traditional strip method, or

with a mechanized system, it is still surgery. Surgery with anesthesia, and potential complications that a technician does not have the training to recognize, prevent, or treat. It is still the responsibility of the surgeon to ensure that the patient is first and foremost unharmed by what we do.

Those who attended the Orlando Workshop viewed two different devices for mechanical FUE extraction and implantation with live patients. The suction assisted FUE machine seemed “really fast” in comparison to the traditional manual approach. Additionally, there are experienced hair transplant surgeons that really like this machine, the decreased surgical time, and the engineering. The machine will not speed the learning curve for the field of hair transplantation, but it will open new avenues to pursue. Suction-assisted FUE may indeed become the standard of care for

the future. In the meantime, this should be viewed as a refinement and complement of a previously well-accepted surgical procedure. It is not a “new technique,” nor is it something that can be mastered by a novice at a weekend course. In most states and countries (if not all), it would be illegal and not within the scope of a technician to perform this procedure. Until all of the cards are on the table, I would caution physicians against allowing

With the expanding number of physicians performing the FUE transplant with what may very well play out to be a great device, the art and science of hair transplant has the potential to be the single fastest growing procedure performed!

their technicians to perform extractions.

Michael Oaks, President of NeoGraft states, “While the technician can be trained to perform the procedure, this is a physician driven procedure, and as such should be *at the least* overseen by a physician.” The cost of the most advanced machine is estimated at \$80,000, quite an investment for most surgeons. The manufacturers of these devices are marketing to not just ISHRS surgeons, but all cosmetic and plastic surgeons. With the expanding number of physicians performing the FUE transplant with what may very well play out to be a great device, the art and science of hair transplant has the potential to be the single fastest growing procedure performed! It is important to maintain the standards the ISHRS has implemented and encourage all providers involved with the FUE transplant to become part of our educational organization.

Just as the technology that introduced the telegraph was rapidly replaced with even more exciting technology (the cell phone, the Internet) we will see this technology expanded and perfected, most likely only to fuel the development of the next great idea. It’s an exciting time to be in hair transplantation!

Much thanks to Dr. Sharron Mason for assisting in the development of this Editor Emeritus column. ✧

Options in revision

from front page

It was in this rather desperate situation, with essentially nothing left to lose (he was going to have to wear a hairpiece otherwise), that led me to recommend what at that time I considered a rather invasive procedure—complete excision of the entire 2.5cm-wide hairline, then reapproximating the defect with suture closure—essentially performing a browlift without the forehead undermining that would be performed to elevate the brows. The prior transplanted hairs contained in this removed strip were dissected out then replanted higher up into the frontal forelock. The scar healed up beautifully, and the patient chose not to have the offered second procedure of grafting into the residual hairline scar once it matured, something I now perform in the majority of these patients.

What made this patient an appropriate candidate, and others like him, were several features. First, the patient really had no other options, other than to wear a hairpiece. As I have performed more and more of them and have developed more confidence in the results, I no longer have this as a requirement. Second, the patient had a decent amount of laxity of the forehead/hairline region, allowing for the removal of the entire transplanted hairline without significant tension on the closure. Third, and very important, the skin along the hairline was also damaged due to scarring from a combination of the prior large grafts and previous attempts to remove the grafts using larger punches. Other important indicators for success include prior attempts at plug removal that simply didn't do enough, and in certain patients, brow ptosis that can be addressed simultaneously with the hairline excision.

While this patient had his entire hairline excised, in approximately one-third of patients, only a portion of the hairline is excised. Most commonly, this will be in the frontotemporal recessions, where the typical patient had poorly placed grafts making the hairline appear too flat. With these partial hairline excisions, the width of frontotemporal scalp excised can be as much as 3.5cm, depending upon the laxity of the scalp, the width of the scalp in this area that is scarred and/or containing of unaesthetic grafts, and whether performed bilaterally (where there will be more tension due to the additional vector of pull) or unilaterally. These partial hairline excisions are performed bilaterally most common, sparing as much as 8cm of the frontal-most hairline.

Whether unilateral or bilateral, the technique is similar. An incision is made right along the leading edge of the affected hairline, then the forehead skin is undermined 3cm or so forward in the subfrontalis muscle plane, then pulled back up to assess how much of the hairline can then be excised. If a browlift is being performed as well, this undermining of forehead skin is extended to the region of the brows to free them up for elevation. The excess hairline skin—hair grafts and all—is removed, and the defect is sutured closed with 2-0 Vicryl to the frontalis/galeal layers, then sometimes with 4-0 chromic to the superficial subcutaneous layer, then with a running 6-0 nylon to reapproximate the skin. To achieve a less detectable nonlinear scar, both incisions are made in a rolling irregular fashion, almost like a “soft” w-plasty.

Bruising and swelling are usually quite minimal unless the browlift is performed. These procedures, even when

incorporating a browlift, are usually performed under local anesthesia with, if desired, oral sedation. If the procedure is being performed without a browlift, limited undermining of the forehead skin to no further than 3cm results in little to no brow elevation, which is something that surprised me at first. The prior transplanted grafts that are contained in the excised hairline skin can be dissected out and re-transplanted into another part of the scalp at the same procedure.

Case Examples

1. 55-year-old man, presented 18 years' status post approximately 200 plug grafts, transplanted into two rows. After full presentation of risks and benefits, patient opted to undergo a linear excision of the entire hairline that contained the grafts, with simultaneous transplanting of almost 700 grafts to the frontal forelock region. Two years later he underwent a second hair grafting procedure of 1,100 grafts, where grafts were concentrated along the fine-line incision scar as well as blending it into the frontal forelock. Photos taken 6 years after this second procedure.

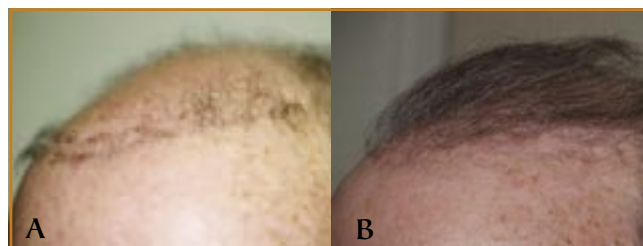

Figure 1. Case 1

2. 22-year-old young man, presented 4 years' status post approximately 400 micro-/minigrafts to bilateral frontotemporal recessions that he soon after regretted. One year earlier, he underwent (by another surgeon) two punch extraction procedures of the prior placed grafts that left his skin with more scarring and still a large percentage of transplanted hairs. Frustrated with the less than acceptable result, he underwent excision of the bilateral frontotemporal recessions (as marked) allowing the scarred skin and the remaining grafts to be excised.

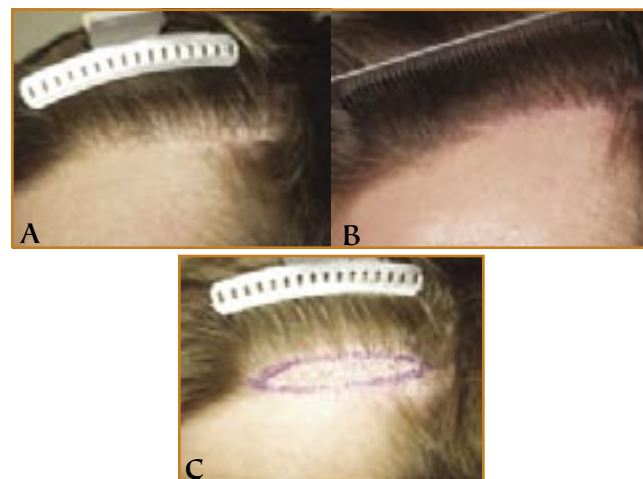


Figure 2. Case 2

Extensive FUE Punch Removal of Grafts

The fundamentals of this technique have been described in the past, but as primarily applied to larger grafts (4 or more hairs), and with certain limitations. Using follicular unit extraction instrumentation, a large number of grafts closely placed together can be removed, with little if any residual detectable scarring. FUE punches of 0.8mm and 1.0mm can be used to extract smaller grafts containing 1-2 hairs and larger grafts containing 2-4 hairs, respectively. The small size of the residual punch hole permits the extraction of hundreds of prior placed grafts in a single procedure; this technique can be used simultaneously with hair grafting in the area.

The biggest challenge to FUE punch extraction is that scarring and fibrosis of the transplanted grafts can sometimes make removal difficult. In some cases not all the hairs in a graft get extracted, so patients are advised that they may desire a second procedure as soon as 2 months later to remove additional grafts. Healing of these extracted sites is quite rapid, with healing by secondary intention (no suturing required) of these 0.8 and 1.0mm punch sites taking place typically in less than a week, and any residual pinkness resolving over several more weeks.

Case Example

3. 44-year-old man, presented 1 year status post approximately 500 grafts to the hairline. His dark, thick donor hairs made the unnaturalness of these 1- to 5-hair grafts more obvious, with their perpendicular angulation and regular distribution appearing totally unnatural. He underwent a single FUE extraction procedure in which over 90% of these grafts were extracted, with the grafts dissected down into smaller follicular units and re-transplanted higher up into the frontal forelock.

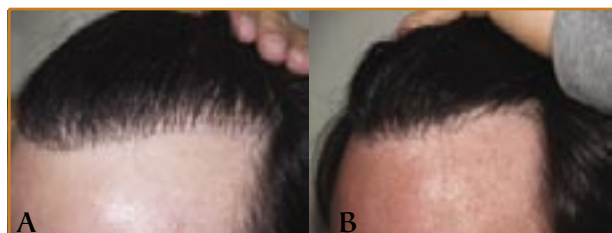

Figure 3. Case 3

Fusiform-Shaped Scalp Reduction Behind the Hairline

Instead of excising the grafts right along the hairline, in some circumstances a similar result can be achieved by performing, in essence, a scalp reduction(s) several centimeters behind the hairline. The main advantage of this technique is that it avoids making any incision along the hairline, which instead is pulled up/back from the fusiform scalp reduction incision. So while this technique improves the position of the hairline, it does not remove unaesthetic grafts or scarred skin along the hairline.

The most common indication for this procedure is for elevating the frontotemporal recessions, either unilaterally or bilaterally. If unilateral, just one scalp reduction incision, typically 4-6cm in length, is made behind the affected frontotemporal hairline, and if bilateral, two incisions are made,

each one behind the frontotemporal hairlines. By placing the incisions close to the hairline, greater control of the amount of elevation is achieved, and if desired, asymmetric hairlines can be made more symmetric. In other cases, a single midline sagittal scalp reduction made several centimeters behind the frontal-most hairline can achieve a similar result of bilateral frontotemporal hairline elevation. In all of these cases, any prior transplanted hairs contained in the scalp reduction can be harvested and replanted.

Case Example

4. 49-year-old man presented status post a large number of hair grafts to the frontal region with a complaint primarily of his hairline being too flat. Bilateral scalp reductions each measuring approximately 2.5cm in width were performed to elevate the frontotemporal recessions by approximately 1.5cm. The hairs contained in the excised ellipses were dissected out, providing 180 grafts that were then planted along the hairline so as to soften the appearance.

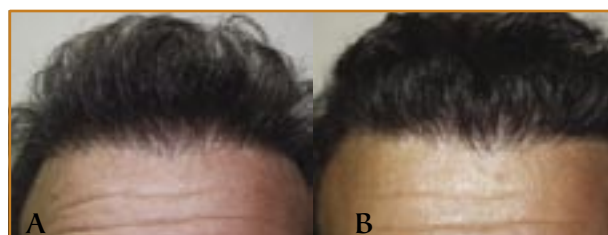

Figure 4. Case 4

Summary

The literature is replete with the descriptions of reparative techniques that involve further grafting sometimes combined with graft removal.¹⁻⁴ For good reason (relative noninvasiveness and patient acceptance), these techniques are quite effective in the majority of patients. In an article that appeared in *Facial Plastic Surgery Clinics*, Vogel nicely described some of the techniques I have written about, in particular the entire hairline excision procedure.⁵ While a much more invasive technique, the appropriate patients simply see few options to having the procedure performed, whether due to scarring of the recipient area that needs to be completely excised or a hairline that is simply too low, and willingly undergoes the surgery that will potentially allow them to resume a life not restricted to the wearing of a hairpiece.

References

1. Lucas, M.W.G. Partial retransplantation: a new approach in hair transplantation. *J Dermatol Surg Oncol.* 1994; 20:511.
2. Vogel, J.E. Correction of the cornrow hair transplant and other common problems in surgical hair restoration. *Plast Reconstr Surg.* 2000; 105:4.
3. Epstein, J. Revision surgical hair restoration: repair of undesirable results. *Plast Reconstr Surg.* 1999; 104:1.
4. Bernstein, R.M. The art of repair in surgical hair restoration—part II: the tactics of repair. *Dermatol Surg.* 2002; 28:10.
5. Vogel, J.E. Correcting problems in hair restoration surgery: an update. *Facial Plast Surg Clin N Am.* 2004; 12:263. ♦

Options in revision

from page 79

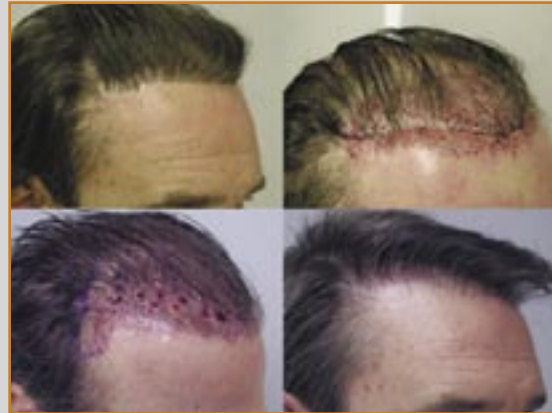A note from Jim Vogel, MD Owings Mills, Maryland jevps@comcast.net

Dr. Epstein has summarized well his techniques and approach to repairing unsightly hair transplants due to poor surgical practice or outdated techniques, which are often made worse in the face of progressive hair loss. Corrective hair restoration surgery is a small but important subspecialty within our field. As Dr. Epstein has nicely demonstrated, these methods provide patients a tremendous improvement in self-esteem and a new lease on life.

The techniques presented are, admittedly, not new. However, what is relatively new in the armamentarium is the use of FUE in repair surgery. Dr. Epstein's third case nicely illustrates the use of FUE in repair of unsightly grafts. However, while FUE using 0.8mm or 1.0mm punches has the advantages mentioned in the article, larger plugs, which are 3-4mm, often require larger punches in the range of 2-3.5mm (I add an example to illustrate this comment). Surgeons should not be concerned with secondary healing of these larger excisions and be assured that a smaller punch will not be as effective in these circumstances.

A stated purpose of the article is to "demonstrate the

proper applications of these techniques...." The fact is that many pluggy hairlines or hairline position problems require repair with surgical procedures that require significant surgical training and experience. Paradoxically, more invasive procedures often result in softer, more natural results than the less aggressive grafting procedures that created the unnatural appearance.



An example of a patient in whom a pluggy hairline was treated with linear excision and recycled grafts immediately planted into forelock and hairline. No separate donor harvest was performed. Eight months later additional intense 4mm plugs were removed with 3.5mm punches, and additional hairline grafting was performed using recycled hair and primary donor harvest. Final result is seen 18 months following the first procedure.

TOPPIK® MAKES THINNING HAIR LOOK FULL AND NATURAL IN 30 SECONDS

Toppik fibers are pure keratin, colored to match the 8 most common hair colors (black, dark brown, medium brown, light brown, auburn, blonde, gray & white). You simply hold the Toppik container over the thinning area and shake it in. In seconds, the fibers combine with the patient's remaining hairs to give the undetectable appearance of a fuller head of hair.

Toppik resists wind, rain and perspiration. It is totally compatible with all topical treatments for hair loss. And Toppik is ideal when used in conjunction with hair transplant surgery, as it effectively conceals any post-operative thinning.



BEFORE



AFTER



All 8 colors

Black, Dark Brown, Medium Brown, Light Brown, Auburn, Blonde, Gray and White.

Call for a
FREE!
TESTER KIT

Phone: 888-221-7171
For international calls dial,
310-207-6300
Fax: 310-207-6302
info@toppik.com
www.toppik.com