

Hair Transplant Forum International Volume 23, Number 5

Hair Transplant Forum International is published bi-monthly by the International Society of Hair Restoration Surgery, 303 West State Street, Geneva, IL 60134 USA. First class postage paid at Chicago, IL and additional mailing offices. POSTMASTER: Send address changes to *Hair Transplant Forum International*, International Society of Hair Restoration Surgery, 303 West State Street, Geneva, IL 60134 USA. Telephone: 1-630-262-5399, U.S. Domestic Toll Free: 1-800-444-2737; Fax: 1-630-262-1520.

President: Carlos J. Puig, DO
cpuig@hairrestorationhouston.com

Executive Director: Victoria Ceh, MPA
vceh@ishrs.org

Editors: Nilofer P. Farjo, MBChB
William H. Reed, II, MD
editors@ishrs.org

Managing Editor, Graphic Design, & Advertising Sales:
Cheryl Duckler, 1-262-643-4212
cduckler@yahoo.com

Cyberspace Chat: Sharon A. Keene, MD

Controversies: Russell Knudsen, MBBS

How I Do It: Bertram Ng, MBBS

Hair's the Question: Sara M. Wasserbauer, MD

Surgical Assistants Corner Editor:
Ailene Russell, NCMA
arussell@haircenter.com

Basic Science: Francisco Jimenez, MD
Ralf Paus, MD
Mike Philpott, PhD
Valerie A. Randall, PhD
Rodney Sinclair, MBBS
Ken Washenik, MD, PhD

Review of Literature: Marco Barusco, MD
Nicole E. Rogers, MD

Meeting Reviews and Studies:
David Perez-Meza, MD

Copyright © 2013 by the International Society of Hair Restoration Surgery, 303 West State Street, Geneva, IL 60134 USA. Printed in the USA.

The views expressed herein are those of the individual author and are not necessarily those of the International Society of Hair Restoration Surgery (ISHRS), its officers, directors, or staff. Information included herein is not medical advice and is not intended to replace the considered judgment of a practitioner with respect to particular patients, procedures, or practices. All authors have been asked to disclose any and all interests they have in an instrument, pharmaceutical, cosmeceutical, or similar device referenced in, or otherwise potentially impacted by, an article. ISHRS makes no attempt to validate the sufficiency of such disclosures and makes no warranty, guarantee, or other representation, express or implied, with respect to the accuracy or sufficiency of any information provided. To the extent permissible under applicable laws, ISHRS specifically disclaims responsibility for any injury and/or damage to persons or property as a result of an author's statements or materials or the use or operation of any ideas, instructions, procedures, products, methods, or dosages contained herein. Moreover, the publication of an advertisement does not constitute on the part of ISHRS a guaranty or endorsement of the quality or value of the advertised product or service or of any of the representations or claims made by the advertiser.

Hair Transplant Forum International is a privately published newsletter of the International Society of Hair Restoration Surgery. Its contents are solely the opinions of the authors and are not formally "peer reviewed" before publication. To facilitate the free exchange of information, a less stringent standard is employed to evaluate the scientific accuracy of the letters and articles published in the *Forum*. The standard of proof required for letters and articles is not to be compared with that of formal medical journals. The newsletter was designed to be and continues to be a printed forum where specialists and beginners in hair restoration techniques can exchange thoughts, experiences, opinions, and pilot studies on all matters relating to hair restoration. The contents of this publication are not to be quoted without the above disclaimer.

The material published in the *Forum* is copyrighted and may not be utilized in any form without the express written consent of the Editor(s).

President's Message

Carlos J. Puig, DO Houston, Texas, USA
cpuig@hairrestorationhouston.com

*"To be ignorant of what occurred before you
were born is to remain always a child."*

—*Marcus Tullius Cicero*



As we prepare for the October San Francisco meeting, a few colleagues have noted along with me how many papers are offered that seem to reintroduce or reinvestigate ideas that were offered or discussed 25 or 30 years ago. I suppose this observation has been made at some time or another by everyone who has been professionally active for a quarter of a century. Of late, I have been thinking that as an educational society, we have a responsibility to try to minimize these redundancies and reinventions by providing new members with insights about what transpired in the years before they arrived.

Understand, I am not discouraging new eyes looking at old problems. I am suggesting that those minds may be more productive if they, and we, spent a little more time reviewing the details of what was done years ago. We know that we learn more from our mistakes than our successes, and sharing both facilitates the development of the specialty and serves our patients.

The multidisciplinary nature of our society is one of its most important assets. Looking at the same problem from the perspective of different specialties has allowed us to make rapid improvements in both our technologies and their results. It is these multiple viewpoints combined with the acceptance of aggressive, sometimes even harsh, critical communications, true intellectual presentation, and defense that drive our technological improvements.

This problem permeates all of medicine today, not just our specialty. Medical education in general has become so focused on "what they need to know to specialize," that often younger physicians are not aware of the mistakes and successes that precede their introduction to the specialty. I often hear, "I don't need to learn scalp reduction or a Mangubat-Brandy Scalp Lift—they are procedures that have been abandoned or are of limited value." And, yes, it may be true that you do not need to know how to do these procedures to be efficient with today's routine HRS technology, but sooner or later you will see a patient who has had one of these done and is looking for the benefits of contemporary technology. If you do not know the anatomical changes, the impact of the flap on blood supply or wound healing, you may find that both you and your patient are in serious trouble when things do not work out as planned. Last summer I had a patient who had a large squamous cell carcinoma excised from his crown by a local Mohs surgeon who did not appreciate the changes in scalp tissue created by his prior two Juri Flaps. He was unable to close the wound, and left a 7cm×8cm defect open to heal by secondary intent.

The fact is this problem may be getting worse. We know there are medical device companies marketing their HRS equipment by trivializing the physician's role and responsibilities both in treatment planning and in performing the procedure. I feel the ISHRS must reach out to these new physicians and encourage them into proper training, lest sooner or later patients will be harmed, and our profession will carry the blemish for years to come.

We soon will congregate in San Francisco for our 21st annual meeting. My hope is that the new members will find experienced mentors, and the senior members will seek out the new members with whom to share their experience and encourage them to understand the value of becoming "fully trained" hair restoration surgeons. Bob Niedbalski and his Fellowship Training Committee are working to develop an online fellowship training program to help fill this void. Hopefully, it will be ready to launch in 2014. ♦

Co-editors' Messages

Nilofar P. Farjo, MBChB Manchester, United Kingdom editors@ISHRS.org



We have been having debates of late about the role of the assistant in FUE procedures. But what I think we need to be very clear about is that we need our assistants—it is impossible to do our surgeries without them. Back in the good old days when 300 grafts was a large operation, a doctor and an assistant were all that was needed, but now with strip harvesting a team of 10 or more is commonplace. Even with FUE, it is customary to have at least 4 assistants. Making your assistants part of the development of your practice is key to getting them engaged in patient care and the improvement of your technique. The aim is to instill in your technicians a sense of pride in what they are doing. A good way to do this is to ensure they view the post-operative results—either by seeing the patient when they return for a follow-up or by seeing the post-op photographs. Also, it's important for assistants to see the problems that can arise, which can be done by including them in your morbidity and mortality case reviews.

Sometimes your team members may look at things from a different angle or come up with an idea that you hadn't thought about. And sometimes it's the little things that count. Let me give

an example. For many years, we used Chinagraph pencils for marking up the recipient area before using a surgical marker so that the patient could have a look and we could make adjustments. These pencils became difficult to obtain and also their composition changed so they didn't mark as well. So we then tried Kohl eyebrow pencils, but we couldn't get them to draw well on the skin either. The oil from the patient's skin made it difficult to mark up. After having bought several different makes, I was getting increasingly frustrated. Then one of our assistants said, "Just put the pencils in the fridge and they'll draw okay." And presto, problem solved.

One of the key things we did when we designed our new clinic was to engage the staff in its development. We looked at their needs, not just at those of the patient. So we made sure that the surgeries had easy to clean benching and flooring, good ventilation, ergonomic chairs, and excellent lighting, for example. Staff changing areas and lunch room needed to be of sufficient size and comfort so that staff could have their own areas to relax. Finally, we developed training rooms so that we could do either small group seminars or larger scale teaching. Ongoing training is a very important part of our staff development. Some of it is compulsory, but some is optional, and it is up to the individual team member to choose whether they move up the development path. ♦

William H. Reed, MD La Jolla, California, USA editors@ISHRS.org



I was excited to read our president's message in the last *Forum* and to learn that the ISHRS is taking steps to financially support well-designed research protocols by small groups of independent physicians. To me, it affirms that the ISHRS is dedicated to coordinating and educating individual physicians in the face of consolidation that seems to be occurring throughout the world of free markets and capitalism—from retail and Walmarts to

health care and Hospital Corporation of America and United Healthcare Insurance Company.

I was also encouraged to learn of business models wherein group practices, such as DHI as Dr. Puig noted, are patient focused...at least for the time being. What concerns me is what happens to a business model as it matures and its founders fade away, and their ethics and high ideals are replaced by, well, business mind-sets. I have long felt that one of the historically consistent ideal relationships is that of the healer with his or her patient. As physicians, we have been given the opportunity and perhaps the responsibility to participate in realizing the high ideals of our profession for the benefit of our patients.

I have lived through a period in the United States when I have seen firsthand the doctor-patient relationship decimated by the business model and capitalism. The doctor-patient relationship has fallen victim to "efficiencies" whose impact has stolen the time and therefore the ability to relate to one's patients in a manner that can preserve the healing nature of the physician's art. The doctor's relationship to the patient has become of secondary importance to business concerns, i.e., to maximizing profits.

My concern about group practices is that sooner or later with the progression of capitalism they are taken over by a publicly traded company where maximizing stockholders' return on investment is of paramount importance. At some point, a hatchet man is brought in to be CEO to squeeze profits for the bottom line and for the shareholders' dividends. We've seen this too many times to need further convincing that this is the progression of capitalism. Some have called it Social Darwinism. None of us would argue that an hour for a patient consultation is a wonderful option we have, but a luxury that can be trimmed by the Hatchet Man in the name of efficiency.

Not long ago I came across the Frankfurt School of Neo-Marxism. They were stuck on the question of how modern Europe at the peak of its sophistication and self-development could produce a fascism that was strong throughout Europe and produced such inhumane behaviors. Their conclusion was the Age of Enlightenment and its Reason produced men who, when in power, were capable of applying reason that was divorced from the rest of their non-rational selves including any empathy for others. He's the Hatchet Man CEO. He is praised by his circle of capitalists who concur that his mission and the mission statement of the capitalistic corporation is to maximize profits, period.

While the Neo-Marxists were in a bind observing that capitalism produced fascists, and Marxism, the Gulag, we physicians need not be so stuck. Our precious gem is the physician-patient relationship that is best preserved by a decentralized modus operandi: the individual physician supported by organizations such as the ISHRS that encourage dialogue, friendship, and education. Dr. Puig's call for the individual to get involved in our Society and to participate and even take the

INTERNATIONAL SOCIETY OF HAIR RESTORATION SURGERY

Vision: To establish the ISHRS as the leading unbiased authority in hair restoration surgery.

Mission: To achieve excellence in patient outcomes by promoting member education, international collegiality, research, ethics, and public awareness.

2012–13 Chairs of Committees

American Medical Association (AMA) House of Delegates (HOD) and Specialty & Service Society (SSS) Representative: Carlos J. Puig, DO (Delegate) and Robert H. True, MD, MPH (Alternate Delegate)
Annual Giving Fund Chair: John D.N. Gillespie, MD
Annual Scientific Meeting Committee: Robert H. True, MD, MPH
Audit Committee: Robert H. True, MD, MPH
Bylaws and Ethics Committee: Robert T. Leonard, Jr., DO
Communications & Public Education Committee: Robert T. Leonard, Jr., DO
Ad Hoc Committee on Branding: Bernard P. Nusbaum, MD
CME Committee: Paul C. Cotterill, MD
Subcommittee on EBM and Research Resources: Marco N. Barusco, MD
Subcommittee on Regional Workshops: Matt L. Leavitt, DO (Chair) & Samuel M. Lam, MD (Co-Chair)
Subcommittee on Webinars: James A. Harris, MD
Core Curriculum Committee: Anthony J. Mollura, MD
Fellowship Training Committee: Robert P. Niedbalski, DO
Finance Committee: Sharon A. Keene, MD
FUE Research Committee: Parsa Mohebi, MD
Hair Foundation Liaison: E. Antonio Mangubat, MD
International Relations Committee: Bessam K. Farjo, MBChB
Membership Committee: Michael W. Vories, MD
Nominating Committee: Kuniyoshi Yagyu, MD
Past-Presidents Committee: Jerry E. Cooley, MD
Pro Bono Committee: David Perez-Meza, MD
Scientific Research, Grants, & Awards Committee: Michael L. Beehner, MD
Surgical Assistants Committee: Diana Carmona-Baez
Surgical Assistants Awards Committee: MaryAnn Parsley, RN
Ad Hoc Committee on Database of Transplantation Results on Patients with Cicatricial Alopecia: Nina Otberg, MD
Ad Hoc Committee on FUE Issues: Carlos J. Puig, DO
Ad Hoc Committee on Regulatory Issues: Paul T. Rose, MD, JD
Subcommittee on European Standards: Jean Devroye, MD, ISHRS Representative to CEN/TC 403
Task Force on Physician Resources to Train New Surgical Assistants: Jennifer H. Martinick, MBBS
Task Force on Finasteride Adverse Event Controversies: Edwin S. Epstein, MD

2012–13 Board of Governors

President: Carlos J. Puig, DO*
Vice President: Vincenzo Gambino, MD*
Secretary: Kuniyoshi Yagyu, MD*
Treasurer: Sharon A. Keene, MD*
Immediate Past-President: Jennifer H. Martinick, MBBS*
 John D.N. Gillespie, MD
 Alex Ginzburg, MD
 Sungjoo Tommy Hwang, MD, PhD
 Paul J. McAndrews, MD
 Bernard P. Nusbaum, MD
 David Perez-Meza, MD
 Arthur Tykocinski, MD
 Ken Washenik, MD, PhD
 Bessam K. Farjo, MBChB
 Russell Knudsen, MBBS
 *Executive Committee



Editorial Guidelines for Submission and Acceptance of Articles for the Forum Publication

- Articles should be written with the intent of sharing scientific information with the purpose of progressing the art and science of hair restoration and benefiting patient outcomes.
- If results are presented, the medical regimen or surgical techniques that were used to obtain the results should be disclosed in detail.
- Articles submitted with the sole purpose of promotion or marketing will not be accepted.
- Authors should acknowledge all funding sources that supported their work as well as any relevant corporate affiliation.
- Trademarked names should not be used to refer to devices or techniques, when possible.
- Although we encourage submission of articles that may only contain the author's opinion for the purpose of stimulating thought, the editors may present such articles to colleagues who are experts in the particular area in question, for the purpose of obtaining rebuttal opinions to be published alongside the original article. Occasionally, a manuscript might be sent to an external reviewer, who will judge the manuscript in a blinded fashion to make recommendations about its acceptance, further revision, or rejection.
- Once the manuscript is accepted, it will be published as soon as possible, depending on space availability.
- All manuscripts should be submitted to editors@ishrs.org.
- A completed Author Authorization and Release form—sent as a Word document (not a fax)—must accompany your submission. The form can be obtained in the Members Only section of the Society website at www.ishrs.org.
- All photos and figures referred to in your article should be sent as separate attachments in JPEG or TIFF format. Be sure to attach your files to the email. Do NOT embed your files in the email or in the document itself (other than to show placement within the article).
- We CANNOT accept photos taken on cell phones.
- Please include a contact email address to be published with your article.

Submission deadlines:

December 5 for January/February 2014 issue

February 5 for March/April 2014 issue

Reed Message

from page 159

lead in refining our knowledge reflects what the ISHRS aspires to be as well as reminds us of our responsibilities as individual physicians. Be responsible or, ultimately, become employed by the Hatchet Man.

I remember talking to a technician from a group practice in years past who related the emergence within the group of a layer of middle management who monitored “time efficiencies,” including variables such as overtime, staffing excesses, and equipment usages. There’s nothing wrong with this as long as it doesn’t dehumanize the patient’s experience and relationship with the doctor and his or her staff. Such intangibles are not efficient, however, and, since such concerns involve the patient’s feelings, this empathy is not something the Hatchet Man knows to value. Comfortable staffing levels where the technician is rested

and has time to engage the patient in conversation is inefficient from his perspective.

So to close, the ISHRS is just what is needed by the individual physician. We physicians need to be conscious, however, that the forces of Social Darwinism are always present to co-opt the individualism currently constituting the ISHRS. The ISHRS, as Dr. Puig illustrates, is doing its part by bringing together physicians to accomplish tasks that only a group can do well, well-designed studies in his cited example. If we value our independence, we need to become engaged in the ISHRS to ensure its continuing independence. A Hatchet Man is always just outside the door salivating at the sweet smell of the inefficiencies that constitute Quality not only for our patients but for us and the way we practice medicine. ♦

Notes from the Editor Emeritus

Dow B. Stough, MD Hot Springs, Arkansas, USA db4@cablelynx.com

The author reports no conflicts of interest and no consulting relationship with Pacira Pharmaceuticals, Inc.



Say goodbye to post-op pain medications?

When I read the efficacy and safety data from clinical trials introducing a new single dose, non-opioid local anesthesia, I was excited. Bupivacaine liposome injectable suspension represents an old drug that has been reformulated with novel liposomal technology. The trade name for this drug is Exparel®, available through Pacira Pharmaceuticals. It is touted as the only single-dose analgesic that provides up to 72 hours of post-op analgesia; the technology used to reformulate bupivacaine is known as Depo Foam (the product delivery platform). This multivesicular liposomal technology can encapsulate a drug without altering its molecular structure. The drug is then released slowly over a desired period of time. The pharmacokinetic profile supplied by the company is impressive. It demonstrates plasma levels of bupivacaine persisting for up to 96 hours after administration. Keep in mind that any systemic levels of bupivacaine following the local administration cannot be correlated to local efficacy. It is important to remember that the rate of systemic absorption of any local anesthetic is dependent upon the route of administration, the method of administration, and the vascularity of the administration site. Local anesthetics for scalp use generally do not have the persistence in efficacy as elsewhere in the body. The scalp is vascular and local anesthesia may be carried off quickly with a resultant short-lived duration. I believe that there is a pressing need for a longer acting local anesthetic for our specialty.

Now back to Exparel. Could this new local anesthetic be the answer? We offer an elective procedure that can present challenges in the management of post-surgical pain. Even with the current FUE techniques, pain can be an issue. A physician has to be astute enough to separate the drug seekers from those with true post-op surgical pain. Then there are issues of dosing narcotics based on body weight, the route of administration, and the rare allergic reaction. It certainly has been my experience that most individuals allergic to “codeine-derived” products are simply describing an episode of severe nausea. Could all of these concerns simply vanish with a single, novel local anesthetic? No more prescriptions, no more nausea, no more calls. Now granted, I am glad to hear back from my patients on their status, but I don’t get particularly excited when they report nausea, post-op vomiting, or the ineffectiveness of my post-operative pain regimen. And yes, the issue of driving while under the influence of opioids must be addressed as well. A long-acting effective local anesthetic would negate all of these concerns.

In pivotal Phase II trials, Exparel was administered using a standard anal block procedure prior to hemorrhoidectomy. The perianal tissue was infiltrated in a fan-like fashion. One hundred and eighty-nine subjects participated in the trial; half were given placebo and the other half Exparel. While the results were quite impressive, my thoughts kept wandering to the unfortunate group of subjects who received placebo after a hemorrhoidectomy. Back to the Phase II trials, the findings showed almost a 50% decrease in opioid consumption. There was a significant increase in time

to the first opioid use among subjects receiving Exparel. Most importantly, three times more Exparel patients were opioid free at 72 hours. The placebo group did not fare as well. Without going into a lot of detail, let’s just say this was an impressive study demonstrating the effectiveness of this long-acting liposomal bupivacaine. Bupivacaine is not without its concerns. While there was no QTC prolongation and no cardiac events in this study, these possibilities certainly linger in the back of my mind. The company points out there are no significant interactions of this with epinephrine, corticosteroids, antibiotics, or non-steroidal anti-inflammatory or oral opioids.

Armed with all the available information on this newly approved drug, I planned my course of action. I elected to use Exparel in every single patient that underwent transplantation in our clinic. Prior to the initial strip removal, Exparel was used in initial cases as the only local anesthetic. The drug cost is a factor at approximately \$200 per surgery case, but probably well worth it if it becomes the panacea we are looking for. Exparel is supplied in a ready-to-use aggregate suspension or it can be diluted with normal saline to accommodate administration for a large area, such as the scalp. I elected to dilute it in a ratio of 50/50 with normal saline. I did not receive this suggested dilution from the sales representative or an article...I was just guessing here. This provided exactly 40ml of anesthesia from a 20ml vial. I also did not administer Exparel with a 25 gauge needle as recommended and instead opted for a 30 gauge needle. The Exparel was stored in a refrigerator prior to use and prior to dilution with saline. Once diluted, it was kept at room temperature for the remainder of the case. My initial impression was, “This stuff really hurts.” Nearly all of my patients tolerated this local anesthesia poorly. Well, would it make sense to use Lidocaine prior to administration of Exparel? You can’t! Non-bupivacaine-based local anesthesia, such as lidocaine, causes an immediate release of bupivacaine from Exparel. The injection of Exparel may follow the administration of lidocaine after a delay of 20 minutes or more. Some of my colleagues (not the makers of Exparel) have expressed concerns about the administration of bupivacaine after lidocaine since the receptor sites are already blocked at that time and the patient may not experience the long-acting effects of bupivacaine. At this point, something had to give. Patients simply could not tolerate Exparel at the beginning of the procedure.

After operating on a dozen or so patients, I decided to alter my protocol and administer Exparel at the end of the procedure; at least an hour after the last dose of lidocaine had been given. The result was more impressive. It still hurt, but less. Thus, I believe that when this novel local anesthetic is given at the conclusion of procedure, it does reduce the need for opioids, just as any commercially available Marcaine® or Naropin® would do. I have been performing administration of local anesthesia to the donor site at the end of procedures for my entire career and believe

Editor Emeritus

from page 161

it is helpful. Is Exparel better than generic bupivacaine in the above setting? Maybe.

The unanswered question is, "How much longer is the pain relief patients actually experience?" I have no doubt this product is wonderful for hemorrhoidectomy patients and other post-operative surgical procedures. I'm just not convinced it is significantly better than the existing bupivacaine when used in the manner described above. It definitely works. It definitely

hurts. To determine how much better will take years to sort out, new dilutional ratios, several thousand patients, and the input of ISHRS physicians.

This editorial was not meant in any way to be a review of Exparel. There are other issues you need to read about concerning this drug. Be careful in patients with hepatic disease, because it is metabolized by the liver. I do, however, encourage you to try Exparel as the potential is there. Google it on the Internet, contact the representative, ask about pricing, and give it a whirl.

The author has no past, present, or future consulting agreement with Pacira Pharmaceuticals, manufacturer of Exparel. ♦



21st ISHRS Annual Meeting in San Francisco

COLE INSTRUMENTS

SALES@COLEINSTRUMENTS.COM
WWW.COLEINSTRUMENTS.COM
1 800 368 4247

Powered Cole Isolation Device (PCID)

Fastest FUE Extractor

Lowest Transection Rate

Direct Training and Marketing Available

Cole Instrument Punches

Sharpest Punches

Precise Depth Control



Ask about our show specials!

**ISHRS EUROPEAN HAIR TRANSPLANT WORKSHOP**

Hosted by Dr Jean DEVROYE

BRUSSELS / BELGIUM

13-15 JUNE 2014

LIVE SURGERY WORKSHOP**Focusing on the Complementary Approaches of FUT & FUE**

- ✓ FUT-strip and FUE: compare, contrast and examine both techniques for each patient suitability
- ✓ Combine both methods on the same patient to achieve the best results
- ✓ Analyze each step of a hair transplant focusing on quality
- ✓ Learn more about alternatives: body hair and scalp micropigmentation
- ✓ Observe 6 live procedures and interact with our Faculty Members
- ✓ Discuss and exchange your knowledge during our "breakfast with the experts"
- ✓ Enjoy 3 days in the Capital of Europe

International World Class Faculty

John P. Cole, MD	José Lorenzo, MD
Alex Ginzburg, MD	Ronald L. Shapiro, MD
James A. Harris, MD	Bradley R. Wolf, MD
Koray Erdogan, MD	Jean M. Devroye, MD



For More Information & Registration

www.European-Hair-Transplant-Workshop.com



Scalp biopsy

from front page

There were also numerous exclamation mark hairs, a diagnostic feature of alopecia areata. The history and atypical presentation warranted a biopsy. A biopsy site was selected at the periphery of the alopecic area, and included a pustule (Figure 2). A 4mm punch biopsy was obtained, and the wound was closed with 4-0 Nylon. Histopathology revealed the findings of a non-inflammatory alopecia consistent with alopecia areata. No features of lupus were seen. Based on these findings, a diagnosis of alopecia areata was made, the plaquinil was discontinued, and intralesional injections of triamcinolone were initiated. If necessary, immunohistology specimens would have been obtained.

Case 2

This 31-year-old Caucasian man presented with a long history of inflammatory hair loss treated with intralesional injections of triamcinolone. Examination revealed extensive patchy inflammation and follicular pustulosis (Figure 3). Figure 4 shows an example of a poor choice for a biopsy site. The extensive inflammation present might obscure important diagnostic features. Figure 5 shows a better biopsy site. Histopathology revealed the

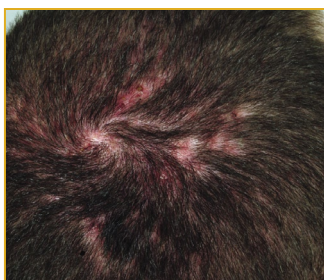


Figure 3. Patchy inflammation and follicular pustulosis.

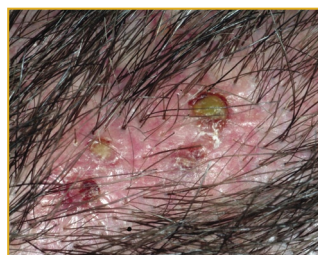

Figure 4. Potentially poor biopsy site due to extensive inflammation.

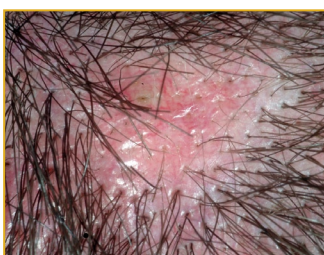

Figure 5. Chosen biopsy site with less pronounced inflammation.

diagnostic features of folliculitis decalvans.

Case 3

This 50-year-old Caucasian woman presented with a many year history of slowly progressive frontal hair loss. There was no history of skin disease elsewhere on her body. Examination revealed evidence of scarring and perifollicular erythema (Figure 6). A biopsy site was selected near the periphery of the alopecic area and it included several inflamed follicular orifices. Histology revealed the findings of lichen planopilaris (LPP).

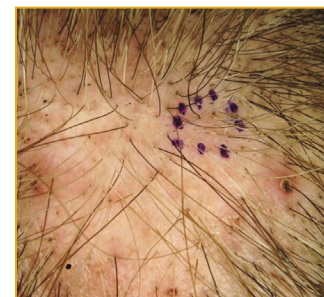


Figure 6. Scarring and perifollicular erythema and selected biopsy site at periphery.

Case 4

This 48-year-old Caucasian woman presented with a long history of facial papular mucinosis (Figure 7), and the more recent onset of hair loss involving the scalp and eyebrows. Examination

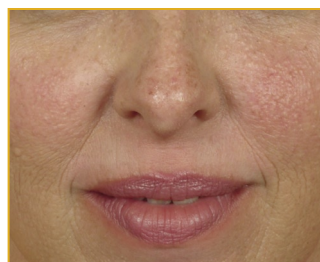

Figure 7. Facial papular mucinosis.

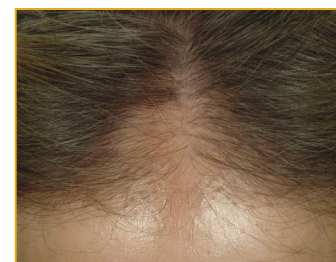

Figure 8. Perifollicular erythema and scarring.

revealed perifollicular erythema and scarring changes (Figure 8). The history and findings produced a differential diagnosis of alopecia mucinosis and LPP, and warranted a biopsy. In this case, a biopsy site was selected from the center of the affected area due to a cluster of affected follicles (Figure 9). A 4mm punch biopsy was obtained, with special stains revealing no mucin deposition, and with routine histology revealing the findings of LPP.

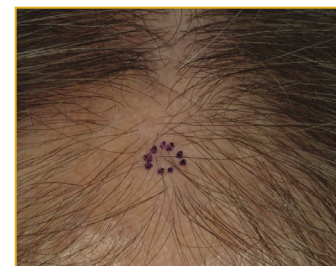

Figure 9. Closeup of affected area showing centrally located biopsy site.

The biopsy technique itself is fairly straightforward. Required equipment includes a 4mm punch biopsy, sharp dissection scissors, forceps, and materials to place one or two sutures (Figure 10).

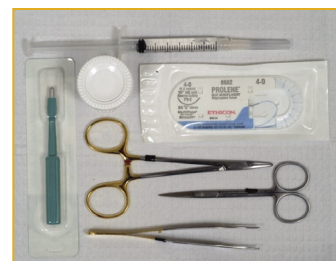

Figure 10. Supplies needed for punch biopsy.

After administration of local anesthetic (Figure 11), hairs to be captured in the punch are trimmed (Figure 12). The punch is angled parallel to the hair shaft direction to minimize hair shaft transection (Figure 13), and gently rotated until the blade has fully penetrated the scalp (Figure 14). Expect a lot of bleeding at this point due to the generous vascularity of the scalp (Figure

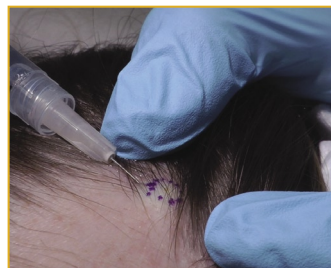


Figure 11. Administration of anesthetic.

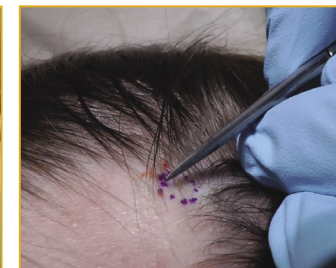


Figure 12. Hairs are trimmed.

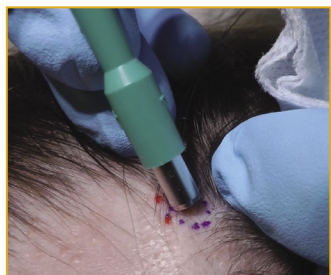


Figure 13. Punch is angled parallel to the hair shaft.

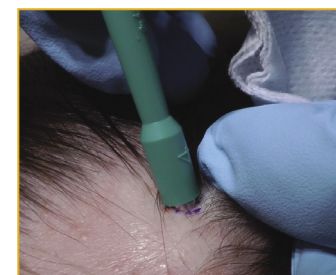


Figure 14. Rotate until blade penetrates scalp.

Scalp biopsy

from page 163

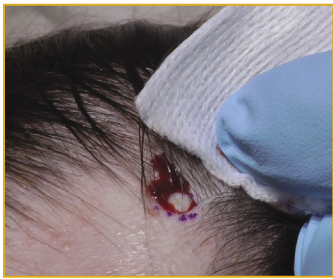

Figure 15. Bleeding due to vascularity of scalp.

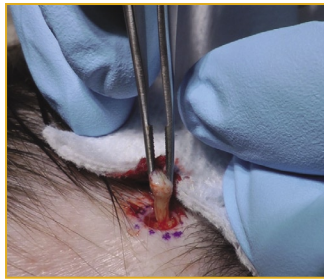

Figure 16. Grasp and elevate with forceps.

15). Using forceps, gently grasp and elevate the specimen (Figure 16). In some scalps, the specimen will separate easily from the underlying tissue without cutting. If necessary, using sharp dissection scissors, free the specimen from its deep dermal attachment. Close the wound with two interrupted 4-0 Nylon sutures or other closure of choice (Figure 17), and be prepared to


hold pressure on this wound for a few additional minutes until bleeding has fully abated.

Most scalp conditions can be diagnosed with a single 4 mm punch specimen, which can be transected for processing in both vertical and horizontal orientations. At times, a second specimen may be required. Thus, working closely with your dermatopathologist is important to ensure that the desired specimens are submitted.

Mastering the punch biopsy technique is fairly trivial for a scalp surgeon, but it is crucial for proper patient care. Sending a patient to a dermatologist for a scalp biopsy can entail a delay of many months and the patient may incur significant expense. Handling this yourself will result in a speedier diagnosis and allow initiation of proper management more quickly. ♦

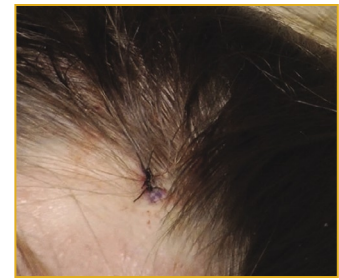

Figure 17. Wound closure with 4-0 Nylon.




Kenny Moriarty
Vice President

Cell: 516.849.3936

Kenny@georgetiemann.com
www.atozsurgical.com

**LED attachment
now available!**



NEW F.U.E. DEVICE

A to Z is now offering Mini Alphagraft with contra angled or straight angle; with more torque. Don't miss out call Alphagraft Hair Implant Inc. or A-Z Surgical today! Ask about FREE punches with your purchase.

www.atozsurgical.com