

Complications and Difficult Cases

Marco N. Barusco, MD Port Orange, Florida, USA drbarusco@tempushair.com



For this issue I decided to submit another one of my cases. I think it is an interesting presentation and one that I have seen a few times. There are many patients who are facing the permanent cosmetic damages caused by the treatment of a cancer or disease. With careful evaluation, planning, and execution, we may be in a position to help them get closure in this chapter of their lives by improving their cosmesis and therefore their quality of life.

Follicular Unit Transplantation on Irradiated Scalp

Background

Patient is a 32-year-old male who came to our office for consultation in 2013 regarding hair transplantation in an area of his right scalp from which hair was lost after surgery and a series of radiotherapy treatments for a meningioma.

As a quick review, meningiomas are some of the most commonly diagnosed brain tumors, accounting for up to 34% of all primary tumors of the brain and central nervous system.¹ Nine out of 10 meningiomas are benign, but their intracranial location and growth over time can lead to serious and sometimes life-threatening consequences (seizures, loss of vision, memory impairment, motor deficits, etc.).² Meningiomas are derived from Arachnoid Cap cells and are usually encapsulated.

Once diagnosed, treatment may include surgery, radiation therapy, or both. The decision on treatment is dictated by the location and size of the tumor mass.²

In this case, the patient was submitted to surgical excision of most of the tumor mass, followed by a series of radiation treatments. He is currently tumor-free but is dealing with the permanent consequences of the surgery and radiation.

Radiation treatment has documented effects on skin and hair. These effects vary greatly according to the location of the skin that is radiated, the overall health status of the patient at the time of the treatment, the patient's healing characteristics, and, of course, the amount of radiation given.³ Traditionally, the scalp is one of the skin areas most resistant to the damages of radiation, with the anterior surface of the neck being the most sensitive. Curiously, even though the scalp skin is the most resistant to radiation damage, scalp hair is more sensitive to radiation than hairs in other areas of the body. Individuals with light-colored skin and hair are usually more sensitive to the damages of radiation.³ In this patient, this held true as his hair was permanently damaged but his scalp skin showed little damage.

Case Presentation/History

The patient was diagnosed with a brain mass consistent with a meningioma. He had a series of MRIs to track the evolution of the mass and, due to its enlargement and the beginning of a mass effect in his brain, surgery was indicated to extract the tumor. In 2010, the patient underwent a right frontoparietal craniotomy with stereotactic volumetric resection of the brain tumor. Pathology confirmed the diagnosis of a meningioma. Since there were no signs of tumor in the skull, the craniotomy was repaired using plates and screws, without the use of other synthetic materials (Figures 1 and 2). The patient had an uneventful recovery and no neurological sequelae from the procedure. In order to

further treat the meningioma, a series of radiation treatments were indicated, which were completed by the patient.

As far as the meningioma, follow-up MRIs so far have not revealed any recurrence. However, the radiation treatments left the patient with a large area of hair loss, which makes it impossible for him to cover with his remaining hair (Figures 3-6). Shaving his head is also not an option for him, since the scars from the craniotomy would then be visible, which is why he is considering the option of a hair transplantation procedure.

The patient is otherwise healthy. He is on no medications with the exception of Keppra (Levetiracetam) 500mg twice a day for seizure prevention (has never had a seizure). He is allergic to Reglan (metoclopramide). He works full-time as a music technician and is engaged.

Regarding his hair loss, the patient has no history of AGA in either side of his family. He denies having noticed any hair thinning in other areas of his scalp.

Physical Examination

On physical examination, the patient presents as a healthy 32-year-old male. General physical exam is completely normal, other than the signs of the craniotomy and the area of hair loss on the right frontoparietal scalp. Neurological exam is completely normal, with no motor or cognitive deficits.

Scalp exam reveals a large area of hair loss (Figures 3-6). The skin over the area is normal, but with no remaining pores or vellus hairs. Upon questioning, the patient states that during the radiation treatments the skin in this area became red and irritated, with a few small ulcers that healed completely after the series of treatments was finished. His hair never grew back in these areas. He has no hyperesthesia in this area, and feels the skin is slightly numb. Palpation of the skin in this area reveals good capillary refill and no soft spots. The hardware from the craniotomy is neither visible nor palpable through the skin. There is also a visible vertical temporoparietal scar on the right side,

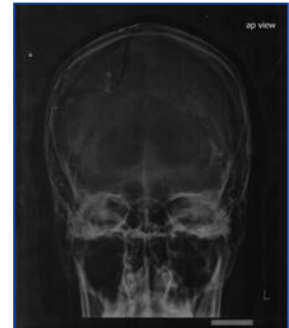

Figure 1. Pre-op X-ray, AP view

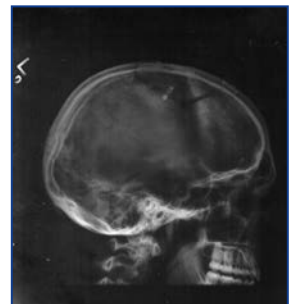

Figure 2. Pre-op X-ray, lateral view

and a visible sagittal midline scar on the frontoparietal. These scars connect posteriorly, marking the incisions in the skin that permitted the anterior deflection of the scalp to permit access to the operative area.

Otherwise, the patient has medium to coarse caliber hair, with an average density of 95 follicular units/cm². No miniaturization is seen anywhere in his scalp.

After a lengthy discussion with the patient and his fiancée, it was determined that the patient would be a good candidate for a follicular unit transplantation (FUT). We discussed both strip harvesting and the FUE method, but due to the bigger chance of follicular unit damage in FUE harvesting and the fact that the skin in the recipient area was not normal skin, the patient and I decided that the technique with the least amount of risk would be strip harvesting. Standard risks of the procedure were discussed, including the probable need for a second hair transplant procedure to increase density, as well as other potential risks that apply to his particular situation, namely: 1) poor growth of the follicular units due to the radiated skin; 2) the possibility of recipient area necrosis due to the potential damage to the microvascular network from the radiation; 3) a remote but real possibility of infection of the hardware used in the craniotomy, which would result in possible in-hospital treatment and another neurosurgery to remove the infected hardware.

A phone conference with the patient's neurosurgeon was also conducted, and medical clearance for the procedure was obtained from him. The neurosurgeon agreed that the risk of infection to the hardware was low, as long as care was taken during the hair transplant procedure and patient was put on antibiotic coverage before, during, and after the surgery.

Having had ample time to consider the above, the patient decided to proceed with the surgery.

Intervention

1. Pre-operative management

- a. Mupirocin ointment to both nostrils three times daily was started 3 days prior to the procedure and continued for a total of 5 days (MRSA prevention).

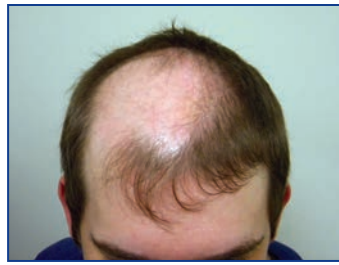

Figure 3. Affected area, frontal view

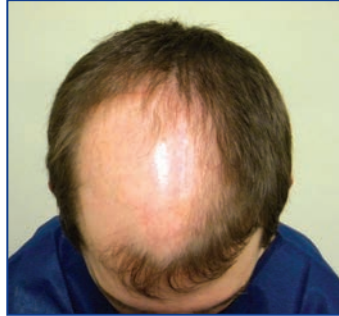

Figure 4. Affected area, top view

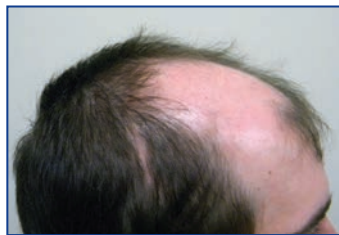

Figure 5. Affected area, right lateral view

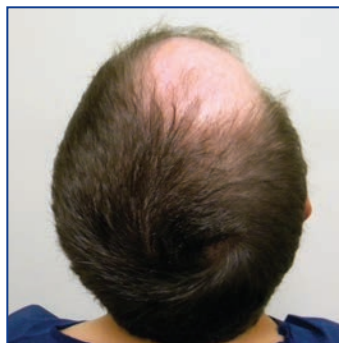

Figure 6. Affected area, posterior-superior view

- b. Patient's hair and body (except his face) was cleansed with Hibiclens (4% chlorhexidine) once daily starting 3 days before surgery.

2. Intra-operative management


- a. The operating room was prepared to afford surgery under sterile conditions with sterile drapes, sterile surgical table covers, etc.
- b. One hour before the procedure, patient received 2g of amoxicillin orally. (This is the recommended protocol for prevention of bacterial endocarditis and bacterial infection of prosthesis during dental and dermatological procedures.)
- c. After pre-operative photographs and marking had been completed (Figure 7), the patient's hair was washed with chlorhexidine. Once applied, the chlorhexidine was not rinsed but only towel dried.
 
- d. Planned occipital strip of donor tissue was marked, taped, and shaved according to our normal protocol.
- e. Before anesthesia, the skin was prepared again with Hibiclens.
- f. Sterile drapes were applied to establish a sterile field, which exposed only the shaved strip of donor hair to be removed.
- g. Donor harvesting was done per our usual protocol. After sutures were applied, the suture line was covered with Bacitracin ointment and was occluded with sterile Telfa and sterile gauze, followed by a compression headband with an ACE bandage.
- h. Hibiclens solution was used to prepare the recipient area of the scalp.
- i. A hole was cut in a sterile drape, large enough to be placed snugly over and around the patient's scalp, exposing the recipient area. Ring block was performed around the recipient area with Lidocaine 2% with Epinephrine.
- j. No tumescence or super-juice of Epinephrine was used in the recipient area, in order to preserve the vascular supply as much as possible.
- k. Under sterile conditions, the recipient sites were made. Custom cut blades were used, mainly to limit the depth of the incisions. Dense-packing was avoided. Instead, we opted for even distribution of hair, knowing that the patient would come back if necessary for a second surgery for density.
- l. During the course of the hair transplant procedure, extra precautions were taken to maintain a sterile field.
- m. The patient tolerated the procedure well. A total of 2,463 follicular unit grafts were transplanted. The procedure was finished with no complications (Figure 8).
- n. The patient was instructed to return to the office the next day for a post-operative evaluation and hair wash.

Figure 7. Surgery plan, marked area of proposed surgery

Complications from page 135

3. Post-operative management

- a. The patient was prescribed pain control according to our standard protocol.
- b. He was instructed to take Cephalexin 500mg tablets three times a day for 10 days.
- c. Hair washes were performed daily at the office.
- d. He was treated with low level laser therapy in the office starting on the day of surgery and every other day thereafter until time of suture removal.

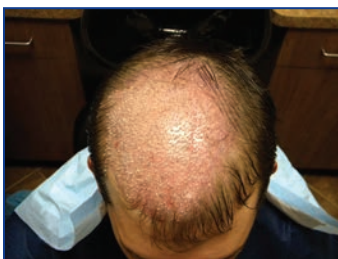

Figure 8. Immediate post-op, grafts in place

Patient Evolution

The patient had no post-operative complications. Sutures were removed on day 10 and he healed very well. At the 4-, 8-, and 12-month follow-up appointments, the patient showed steady, even hair growth. At the 12-month appointment, the overall density and growth was assessed. The patient was very pleased with the hair coverage he obtained and how natural it looked (Figures 9-12). The donor scar measured 1-2mm in width.

At this point we discussed a second procedure for added density. This additional procedure was performed on June 2, 2014, following the same procedures outlined before. A total of 1,537 follicular units were added to the area. We expect that the patient will have much better density and coverage once these new grafts grow.

Thoughts and Pearls

- In irradiated skin, care must be taken to assess its thickness, as well as the thickness of the subcutaneous tissue. If the skin is thin and there is little subcutaneous tissue, hair graft survival will probably be impaired.
- Every time there is surgical hardware (plates and screws) in the area where the transplant will be performed, care must be taken to avoid bacterial contamination of the hardware.
- As with any other patient, expectations for results must be clearly discussed and understood, and these patients will more than likely require more than one procedure before they achieve their desired density and coverage.
- In irradiated skin, it is better to use larger, "chubbier" grafts placed further apart to increase the chance of good survival and growth. As mentioned above, density should be achieved via multiple procedures.
- We must keep in mind that there is always the possibility that these patients will develop AGA in the future, so in planning the procedures, we need to make sure that there is enough supply of donor hairs in case other areas of the scalp need to be transplanted.

In closing, this has been a very rewarding experience for the patient and his family, for me, and for our staff. The impact that we as surgeons can cause on a person's confidence and self-esteem cannot be overstated.

References

1. Wiemels, J., M. Wrensch, and E.B. Claus. Epidemiology and Etiology of Meningioma. *Journal of Neurooncology*. 2010(Sep); 99(3):307-314.
2. Claus, E.B., et al. Epidemiology of Intracranial Meningioma. *Neurosurgery Online Journal*. 2005(Dec); 57(6):1098.
3. Balter, S., et al. Fluoroscopically Guided Interventional Procedures: A Review of Radiation Effects on Patient's Skin and Hair. *Radiology*. 2010(Feb); 254(2).
- 4.* Engelhard, H. (n.d.). Current Status of Radiation Therapy and Radio-surgery in the Treatment of Intracranial Meningiomas. Chicago, IL: Division of Neurosurgery, Dept. of Surgery, Northwestern University Medical School.
*Not specifically cited in text but used as a resource. ♦

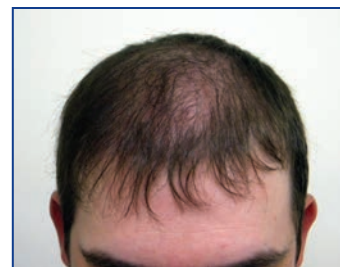


Figure 9. 1 year post-op, frontal view

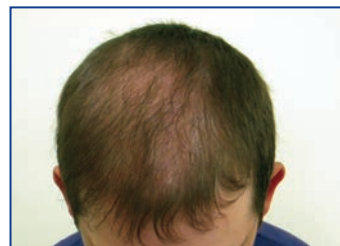

Figure 10. 1 year post-op, top view

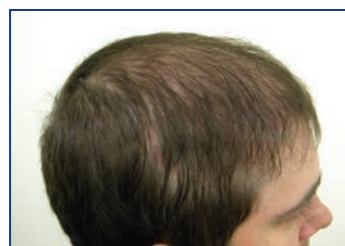

Figure 11. 1 year post-op, right lateral view

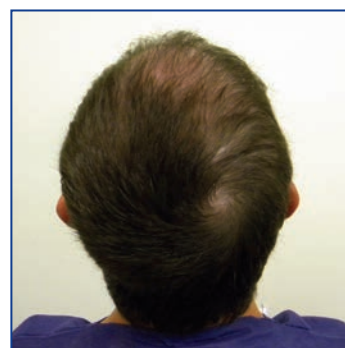

Figure 12. 1-year post-op, posterior-superior view