

## Hair Transplant Forum International Volume 24, Number 4

Hair Transplant Forum International is published bi-monthly by the International Society of Hair Restoration Surgery, 303 West State Street, Geneva, IL 60134 USA. First class postage paid at Chicago, IL and additional mailing offices. POSTMASTER: Send address changes to Hair Transplant Forum International, International Society of Hair Restoration Surgery, 303 West State Street, Geneva, IL 60134 USA. Telephone: 1-630-262-5399, U.S. Domestic Toll Free: 1-800-444-2737; Fax: 1-630-262-1520.

President: Vincenzo Gambino, MD, FISHRS  
[vincenzogambino@vincenzogambino.com](mailto:vincenzogambino@vincenzogambino.com)

Executive Director: Victoria Ceh, MD  
[vceh@ishrs.org](mailto:vceh@ishrs.org)

Editors: Mario Marzola, MD  
Robert H. True, MD, MPH, FISHRS  
[editors@ishrs.org](mailto:editors@ishrs.org)

Managing Editor, Graphic Design, & Advertising Sales:  
Cheryl Duckler, 1-262-643-4212  
[cduckler@ishrs.org](mailto:cduckler@ishrs.org)

Controversies: Russell G. Knudsen, MBBS, FISHRS

Cyberspace Chat: John Cole, MD; Bradley R. Wolf, MD, FISHRS

Difficult Cases/Complications: Marco Barusco, MD

Hair Sciences: Jerry Cooley, MD

Hair's the Question: Sara M. Wasserbauer, MD

How I Do It: Timothy Carman, MD, FISHRS

Meeting Reviews and Studies: David Perez-Meza, MD, FISHRS

Regional Society Profiles:

Mario Marzola, MBBS; Robert H. True, MD, MPH, FISHRS

Review of Literature:

Nicole E. Rogers, MD; Jeffrey Donovan, MD, PhD

Copyright © 2014 by the International Society of Hair Restoration Surgery, 303 West State Street, Geneva, IL 60134 USA. Printed in the USA.

The views expressed herein are those of the individual author and are not necessarily those of the International Society of Hair Restoration Surgery (ISHRS), its officers, directors, or staff. Information included herein is not medical advice and is not intended to replace the considered judgment of a practitioner with respect to particular patients, procedures, or practices. All authors have been asked to disclose any and all interests they have in an instrument, pharmaceutical, cosmeceutical, or similar device referenced in, or otherwise potentially impacted by, an article. ISHRS makes no attempt to validate the sufficiency of such disclosures and makes no warranty, guarantee, or other representation, express or implied, with respect to the accuracy or sufficiency of any information provided. To the extent permissible under applicable laws, ISHRS specifically disclaims responsibility for any injury and/or damage to persons or property as a result of an author's statements or materials or the use or operation of any ideas, instructions, procedures, products, methods, or dosages contained herein. Moreover, the publication of an advertisement does not constitute on the part of ISHRS a guaranty or endorsement of the quality or value of the advertised product or service or of any of the representations or claims made by the advertiser.

Hair Transplant Forum International is a privately published newsletter of the International Society of Hair Restoration Surgery. Its contents are solely the opinions of the authors and are not formally "peer reviewed" before publication. To facilitate the free exchange of information, a less stringent standard is employed to evaluate the scientific accuracy of the letters and articles published in the Forum. The standard of proof required for letters and articles is not to be compared with that of formal medical journals. The newsletter was designed to be and continues to be a printed forum where specialists and beginners in hair restoration techniques can exchange thoughts, experiences, opinions, and pilot studies on all matters relating to hair restoration. The contents of this publication are not to be quoted without the above disclaimer.

The material published in the Forum is copyrighted and may not be utilized in any form without the express written consent of the Editor(s).

## President's Message

Vincenzo Gambino, MD, FISHRS *Milan, Italy*  
[vincenzogambino@vincenzogambino.com](mailto:vincenzogambino@vincenzogambino.com)



As the annual meeting approaches, I would like to take this opportunity to inform you of several important proposed amendments that have been made to the Society's bylaws that you will be voting on in Kuala Lumpur this October. These include the following:

- First and foremost, Article III ("Membership") was amended to include a seventh membership category: the Surgical Assistant Member. The candidate seeking this form of membership must be a licensed medical professional who is employed by a Fellow, a Member, or an Associate Member of the Society and assists in the surgery. Current Surgical Assistant Members who do not meet the new requirements are nonetheless grandfathered in. This new member category would replace the Surgical Assistant's Auxiliary (currently under Article IX).
- A specific section was dedicated to Committees (Article VI). Article VI sets forth the structure, duties, and responsibilities of each Committee, including the appointment and removal of Committee members. In addition to the standing Committees, the President reserves the right to establish new committees as needed.
- Under the amended version of Article VII ("Discipline"), the Board, in its sole discretion, will determine whether a member's action constitutes "immoral, dishonorable, or unprofessional conduct" for the purposes of this provision.

You will soon be receiving emails with a link to the bylaws and all the proposed changes in their entirety.

Furthermore the BOG has initiated an Integrated Communications Strategy to increase ISHRS visibility with the public and media. This is being done on many levels. First priority is to increase the number and duration of visits to the ISHRS website. Equally important is reaching more consumers through magazine articles, TV news and entertainment, and Internet websites, such as Yahoo news. This is an international initiative with articles being translated into five different languages (so far). The ultimate goal is to become a top hit on all of the major search engines when using key words.

These are some of the many important changes being made. I look forward to sharing our other proposals and strategies in the future. ♦

## Co-editors' Messages

Mario Marzola, MBBS Adelaide, South Australia [editors@ISHRS.org](mailto:editors@ISHRS.org)

Here in Australia, the world down under, it's the middle of winter and time to sit by the fire with a beverage and a good journal. We can read in this edition of the *Forum* excellent summaries of many meetings to help us keep abreast of what's happening in our specialty. Well done to all the reporters, in some cases we can actually imagine ourselves being there. That's the art of a good writer no doubt.

I attended the 8th World Congress for Hair Research on Jeju Island in Korea and, sure enough, it turned out to be everything I expected and hoped for. For details, see Dr. Nilofer Farjo's report in the Meetings section. It's a good experiment mixing scientists who work with mice and clinicians who work with humans. Even though we speak the same language it's not easy keeping up with all the acronyms that flow freely in the scientific presentations. There were some speakers who talked of what sounded like a valuable breakthrough until it was explained that now this one breakthrough has opened up two more questions needing answers. Nothing seems easy.

The highlight for me, which is summarized in Dr. Farjo's review, was Dr. Andrew Messenger saying that female pattern hair loss (FPHL) is not androgen dependent and should not be called androgenetic alopecia. He says the genes of male pat-

tern hair loss (MPHL) and FPHL are not the same. Dr. Vera Price and Dr. O'Tar Norwood have been saying something similar since the early 2000s. We have to start listening now.

In a very practical sense, I love Dr. Jerry Wong's description of his use of tumescence, which is highlighted in this issue's "How I Do It" column. In every way it makes a lot of sense to preserve the circulation so it can feed the grafts. How many times have we tumesced and blown up the scalp, thinking surely that will separate the blood vessels from my cutting instrument, blade, needle, whatever. If we are not careful, I would guarantee that nine times out of ten we have placed the tumescence in the sub-galeal plane. If it was easy to inject, and if you are still hitting bleeders, stop and inject like Dr. Wong describes. Simple, easy, helpful, and a lot of common sense. Dr. Wong notes that doing it his way, many patients will pass our hands without hitting one bleeder. How good would that be for better growth of our transplants?

Enjoy your season wherever you may be and we hope you enjoy this, our fourth edition. ♦



Robert H. True, MD, MPH, FISHRS New York, New York, USA [editors@ISHRS.org](mailto:editors@ISHRS.org)

I hope you will enjoy this issue of the *Forum*. How can hair transplantation be improved? In his article on Bio-enhancements, Dr. Jerry Cooley makes a compelling argument that use of biological agents such as liposomal ATP, hypothermasol, platelet-rich plasma (PRP), and ACell do already improve outcomes in hair restoration surgery. This has been my clinical experience as well. In my practice, using these agents is resulting in faster and better healing; is promoting better and earlier growth; and is getting better results in patients at risk for poor growth. Dr. Jerry Wong's description in How I Do It of "variable tumescence" is also noteworthy as a very sophisticated approach. I've already begun to use it and I like what I see so far.

Drs. David Perez-Meza, Ken Williams, and Ricardo Mejia offer an engaging recap of the Orlando Live Surgery Workshop, and Dr. Nilofer Farjo has done a wonderful job in summarizing highlights of the 8th World Congress for Hair Research. My attention was captured by the report of Dr. Rodney Sinclair, which noted attachment to the arrector pili muscle is probably crucial in maintaining the normal cycling of the hair follicle, and loss of this attachment leads to miniaturization and androgenetic alopecia (AGA). There is difference of opinion among us about the impact of splitting follicle groups, whether on the microscope or with the FUE punch. Dr. Sinclair's studies suggest

that such practice could be detrimental when the arrector pili attachment is damaged. And while we are on the topic of FUE and FUT, in Cyberchat, Dr. John Cole points out that we would be more accurate in our clinical descriptions and terminology if we got away from using these fundamentally inaccurate terms.

I really appreciate Ailene Russell's article on patient comfort. I already used it for a staff meeting and we had a very productive discussion. I wonder if you agree with Dr. Russell Knudsen that FUE is not a good procedure for women. I think we will continue discussion on this in the next issue. After you read about Dr. Atodaria's new instrument, I suggest you link to the video to see more clearly how it is used.

Thank you and congratulations to Dr. Greg Williams, the current president of the British Association of Hair Restoration Surgery, for a nice report on the society and its members. I am continually struck by the strength of our professional community worldwide.

Finally thank you again to our columnists, Drs. Marco Barusco, Nicole Rogers, and Sara Wasserbauer, for their always informative installments. ♦



## INTERNATIONAL SOCIETY OF HAIR RESTORATION SURGERY

Vision: To establish the ISHRS as a leading unbiased authority in medical and surgical hair restoration.

Mission: To achieve excellence in medical and surgical outcomes by promoting member education, international collegiality, research, ethics, and public awareness.

### 2013–14 Chairs of Committees

*American Medical Association (AMA) House of Delegates (HOD) and Specialty & Service Society (SSS) Representative:* Carlos J. Puig, DO, FISHS (Delegate)

*Annual Giving Fund Chair:* John D.N. Gillespie, MD, FISHS

*Annual Scientific Meeting Committee:* Damkerng Pathomvanich, MD

*Audit Committee:* Robert H. True, MD, MPH, FISHS

*Bylaws and Ethics Committee:* Robert T. Leonard, Jr., DO, FISHS

*Communications & Public Education Committee:* Robert T. Leonard, Jr., DO, FISHS

*CME Committee:* Paul C. Cotterill, MD, FISHS

*Regional Workshops Subcommittee:* Matt L. Leavitt, DO (Chair) & David Perez-Meza, MD, FISHS (Co-Chair)

*Subcommittee on EBM and Research Resources:* Marco N. Barusco, MD

*Subcommittee Expert Panel:* Paul C. Cotterill, MD, FISHS

*Subcommittee on Webinars:* James A. Harris, MD, FISHS

*Core Curriculum Committee:* Anthony J. Mollura, MD

*Fellowship Training Committee:* Robert P. Niedbalski, DO

*Finance Committee:* Ken Washenik, MD, PhD

*FUE Research Committee:* Parsa Mohebi, MD, FISHS

*Hair Foundation Liaison:* E. Antonio Mangubat, MD

*International Relations Committee:* Bessam K. Farjo, MBChB, FISHS

*Membership Committee:* Michael W. Vories, MD

*Nominating Committee:* Kuniyoshi Yagyu, MD, FISHS

*Past-Presidents Committee:* Jennifer H. Martinick, MBBS

*Pro Bono Committee:* David Perez-Meza, MD, FISHS

*Scientific Research, Grants, & Awards Committee:* Michael L. Beehner, MD

*Surgical Assistants Committee:* Aileen Ullrich

*Surgical Assistants Awards Committee:* Tina Lardner

*Ad Hoc Committee on Database of Transplantation Results on Patients with Cicatricial Alopecia:* Jeff Donovan, MD, PhD

*Ad Hoc Committee on Issues Pertaining to the Unlicensed Practice of Medicine:* Carlos J. Puig, DO, FISHS

*Ad Hoc Committee on Regulatory Issues:* Paul T. Rose, MD, JD

*Subcommittee on European Standards:* Jean Devroye, MD, FISHS

ISHRS Representative to CEN/TC 403

*Subcommittee on Alberta, Canada Standards:* Vance Elliott, MD, FISHS

*Task Force on Finasteride Adverse Event Controversies:* Edwin S. Epstein, MD, FISHS

### 2013–14 Board of Governors

*President:* Vincenzo Gambino, MD, FISHS\*

*Vice President:* Sharon A. Keene, MD\*

*Secretary:* Kuniyoshi Yagyu, MD, FISHS\*

*Treasurer:* Ken Washenik, MD, PhD\*

*Immediate Past-President:* Carlos J. Puig, DO, FISHS\*

Alex Ginzburg, MD

James A. Harris, MD, FISHS

Sungjoo Tommy Hwang, MD, PhD

Francisco Jimenez, MD, FISHS

Melvin L. Mayer, MD, FISHS

Paul J. McAndrews, MD, FISHS

David Perez-Meza, MD, FISHS

Arthur Tykocinski, MD, FISHS

Bessam K. Farjo, MBChB, FISHS

Robert S. Haber, MD, FISHS

\*Executive Committee



### Editorial Guidelines for Submission and Acceptance of Articles for the Forum Publication

- Articles should be written with the intent of sharing scientific information with the purpose of progressing the art and science of hair restoration and benefiting patient outcomes.
- If results are presented, the medical regimen or surgical techniques that were used to obtain the results should be disclosed in detail.
- Articles submitted with the sole purpose of promotion or marketing will not be accepted.
- Authors should acknowledge all funding sources that supported their work as well as any relevant corporate affiliation.
- Trademarked names should not be used to refer to devices or techniques, when possible.
- Although we encourage submission of articles that may only contain the author's opinion for the purpose of stimulating thought, the editors may present such articles to colleagues who are experts in the particular area in question, for the purpose of obtaining rebuttal opinions to be published alongside the original article. Occasionally, a manuscript might be sent to an external reviewer, who will judge the manuscript in a blinded fashion to make recommendations about its acceptance, further revision, or rejection.
- Once the manuscript is accepted, it will be published as soon as possible, depending on space availability.
- All manuscripts should be submitted to [editors@ishrs.org](mailto:editors@ishrs.org).
- A completed Author Authorization and Release form—sent as a Word document (not a fax)—must accompany your submission. The form can be obtained in the Members Only section of the Society website at [www.ishrs.org](http://www.ishrs.org).
- All photos and figures referred to in your article should be sent as separate attachments in JPEG or TIFF format. Be sure to attach your files to the email. Do NOT embed your files in the email or in the document itself (other than to show placement within the article).
- We CANNOT accept photos taken on cell phones.
- Please include a contact email address to be published with your article.

*Submission deadlines:*

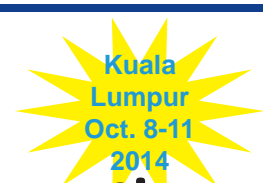August 5 for September/October 2014 issue  
October 5 for November/December 2014 issue



**REGISTER FOR  
THE MEETING!**

**Make Your hotel reservations.**

[www.ishrs.org/AnnualMeeting.html](http://www.ishrs.org/AnnualMeeting.html)



## Notes from the Editor Emeritus

Michael L. Beehner, MD *Saratoga Springs, New York, USA* [mlbeehner@saratogahair.com](mailto:mlbeehner@saratogahair.com)



### MFU Grafts and Strip Harvesting—We Hardly Knew Ye

I am dumbfounded by two “overturning of the tables” that have occurred in our specialty within the past 20 years. First, we granted a very short time on stage to the use of MFU grafts (“mini-grafts”) and quickly ushered them off to the scrap pile of history, replacing them with the arrival of an exclusive “all-FU” approach. Now we appear to be throwing out the donor strip harvest in favor of follicular unit extraction (FUE), which has many potential pitfalls in my opinion.

Maybe we should blame Norman Orentreich for all of this, since he’s the one that couldn’t read Japanese journals and decided upon the unsightly 4mm round plug as the initial choice for the cornerstone of the modern era of hair transplant surgery. If only he had read that Dr. Okuda from Japan long ago figured out that using smaller grafts was the way to go. So what happened? I think the large plugs of the 1970s and 1980s left such a negative impression on everyone that we’ve been trying ever since to run as fast and as far as we can in the opposite direction. In our haste to run away from “large” grafts, we ran right past the brief 5- to 6-year period in which mini-grafts were featured. This all happened around the time I first became involved in hair surgery.

I’ve been using these “medium”-sized MFU grafts ever since in selected patients, and find them a valuable addition to my hair transplant armamentarium. Obviously, you can only obtain them by taking a strip. Their advantages are many: 1) they survive at nearly 100% in several research studies I’ve conducted, and they start growing out promptly at around 3 months; 2) they save the patient money (unless you charge by the hair); 3) they allow the surgeon to better create “gradients” of hair density in an artistic way; 4) they’re very reliable and predictable—they always grow and poor growth is almost unheard of; and 5) best of all—and at the top of the list: they block light from the scalp better than FU grafts. They are a wonderful way to avoid a “see-through” result.

All of that having been said, I am very aware that it is very easy to be un-artistic using these grafts and create detectability that is unacceptable. They must be angled acutely, so that they shingle over each other. They need to be very close together in an irregular/regular way that does not appear as rows. They need to only be used in central areas of the scalp, never near the front hairline or in the vertex. There are some patients whose hair characteristics do warrant using all FUs. Also, it helps to have an informal commitment on the patient’s part that he will come at least two times for surgery, since two passes with these grafts renders them almost undetectable on casual inspection later on. For recipient sites, I favor tiny 1.9mm sagittal slit grafts for females with moderate to severe hair loss, and 1.3mm round holes for males. I prefer using all FUs for women with only mild thinning. For males I offer them a choice of an all-FU approach or a “combination” approach with both MFUs and FUs. I use this combination approach in virtually all of the men who are obviously going to be a Norwood VI some day, which happens to be the majority of my practice. For those with mild frontal loss only, I use only FUs planted closely together. In closing on this subject, I only regret that this selective use of MFU grafts in hair transplantation has become a lost art.

My fear now is that we might be “throwing out the baby with the bath water” with regards to the use of donor strip harvesting. At the 2013 San Francisco ISHRS Annual Scientific Meeting I began to sense a storming head-long toward FUE harvesting as the sole means of harvesting hair grafts. It draws to mind a parade of lemmings lined up in a long parade, all jumping, one after another, over the cliff. FUE started in a big cloud of smoke and mystery. Then, like anything new, a few entrepreneurial hair surgeons and groups began exclusively using this modality. As usual, anything new is usually lauded as the latest and greatest by the sycophants of the Internet, and proclaimed as being better than whatever came before, long before any scientific proof is available for its claims.

To start with, I think the patient’s choice should not be worded as a choice between “FUE” and “strip.” In stating the choice this way, we’re leaving out the biggest distinction between the two methods—namely, the fact that with FUE the graft is “plucked” (a gentle word for “ripped”) out of a hole, while with a strip harvest the grafts are produced with microscopic precision, as perfect as you want them to be, with tissue protecting the graft and a 1mm pad of fat beneath the bulb to use for safely placing the grafts. So I would propose that a better way to describe the patient’s choice, instead of framing the conversation around “strip” vs. “FUE”, is to contrast “microscopic dissection of grafts” vs. “plucking the grafts out of tiny holes, which leave the follicle bulbs naked and stripped of surrounding tissue a large percentage of the time.” For me it’s a no-brainer as to which is the better way to harvest hair for most patients: With a donor strip, you are removing the very best hairs on the head, situated at the mid-level of the “safe” area. These are the hairs that have the best future for longevity and maintaining hair shaft diameter. All you have to do is lay a group of FUE grafts down next to a similar group of microscope-dissected grafts. There is no comparison. Figure 1 is a photo of the 3-hair FUs in the study I describe below, looking at hair survival in FUE and FUT grafts. In the past couple of years, at least a third of my consultation patients inquire about FUE. I go through all of the arguments for and against

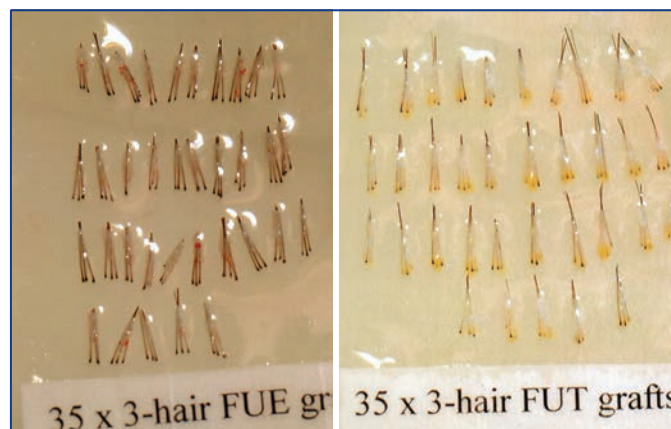

Figure 1. 3-hair FUs used in the described study.

Editor Emeritus *from page 125*

both methods and show them photos; currently, 90% elect to have the strip harvest. It's a lot of extra work on my part to go through this lengthy explanation each time, but in today's climate and with the FUE media blitz still rampaging it is necessary.

Next shocking statement: Despite all of the limitations of FUE, I still think every hair surgeon should know how to perform FUE. There are valuable niches in which I believe it is the method of choice for donor harvesting. I perform at least three FUE cases a month and actually enjoy doing it. My problem is that I don't like how the grafts look compared to the FU grafts I've been using for the past 20 years, and I have strong suspicions that the survival rate is less. Moreover, the great majority of males that I transplant are Norwood VI heads in the making. I truly believe that harvesting enough FU grafts by FUE to adequately fill in a Norwood VI bald scalp will leave an unacceptably thin look and moth-eaten sea of white dots in most patients. Some of the valuable uses of FUE harvested grafts are for placing grafts into old donor scars for camouflage, for harvesting from the beard and chest in desperate situations, and for obtaining grafts from areas of the scalp that are too high or too low to take a strip from. When I perform FUE, I do so with the clear expectation that my survival rate will probably be at least 10% less than with strip grafts.

I completed a study last year on two shiny-bald men, looking at 880 follicles and obtained an overall 53.9% growth of FUE follicles at one year and 85.2% survival of FUT grafts at the same juncture. Because one of the patients may have been an "out-lier," I am doing the same study on two additional patients before publishing the final results. Patient #1 had 74% survival of FUE grafts and 87.3% for FUT. Patient #2 had a dismal 33.6% survival of FUE grafts and 83.2% for FUT. At least one prominent FUE hair surgeon is on record as saying studies aren't necessary, that we know the growth if fine. I don't agree.

Many years ago, Dr. Patrick Frechet, a brilliant French hair surgeon, introduced the use of an elastic "extender" in scalp reduction surgery and the follow-up use of an ingenious "triple flap" to make the final vertex hair directions appear normal. Many surgeons tried to emulate his work and I recall Dr. Richard Shiell commenting several years later that, as brilliant as the technique was, it didn't "travel well." I am willing to concede that there are probably a handful of surgeons out there that are the "Patrick Frechets" of FUE, and who probably get better results than I or the average practitioner does, but I strongly suspect that the technique is not going to "travel well."

To finish up on the subject of FUE, I think a few other important points need to be made. I believe that in the long run, the marketing of itinerant FUE performed by unlicensed technicians will be a serious detriment to our specialty and the public's impression of hair transplant results. In my opinion, the whole scenario is heading toward a large number of unsatisfied patients. Such a strategy appeals mainly to doctors with no significant background in hair restoration surgery or understanding of its nuances and potential complications, giving them the impression FUE hair transplantation is an easy-to-perform, "turn-key" surgery with uniformly wonderful results and significant monetary gain. And now we also have automated robotic instruments, which many are rushing to purchase in order to appear to be on the leading frontier of new and exciting things in hair surgery. As these devices are significantly expensive, I feel that I will need much more evidence that they are better than the SAFE II system, I now use for FUE, before I will make such a commitment.

One of the main selling points of FUE is that it is scarless surgery. This is not true. If two or three passes are made in an attempt to fill in the typical Norwood VI patient, in the great majority of patients there will be so many small white "dots" that it will show and the thin donor density will be an issue. The very goal of choosing FUE so that one can wear their hair short is negated by the dots, and they have to wear their hair longer to cover this in the same way strip patients do. In comparison, for 90% of my patients the resultant scars look fine and are not of any concern to them. Wearing their hair one-half inch long is all that is required.

The last point I wish to make is that, in truth, those of us who perform large strip surgeries of 2,000 grafts and more share some of the blame for this sudden rush to FUE. We have set the bar so high for the expected number of grafts a patient should receive that no one can expect to have a staff and the necessary equipment to produce this large number of grafts.

We have created a "Catch-22," which makes it very hard for anyone to get started and practice in the manner that we do. I'm not sure what the answer is. Wonderful live surgery workshops now abound all over the world and are certainly a good start. Perhaps the answer lies in having pools of surgical techs that could work for different surgeons in a geographic area as they are needed. That whole concept has potential pitfalls also, as we all know. I would only urge that all hair surgeons slow down the rush to FUE, look at its positives and negatives, be competent in both FUE and in strip harvest with microscopic dissection, define for your practice those niches where FUE can rightfully play a role, and, above all, do for each patient what will work best for him or her. If you are too greedy with either technique, taking either too wide of a strip or using FUE on too large a percentage of the native follicular bundles in the donor area, you will be creating unhappy patients and the negative public opinion resulting will hurt us all. ♦



Instruments, Inc.

**State-of-the-art  
instrumentation for hair  
restoration surgery!**

***For more information, contact:***

**21 Cook Avenue  
Madison, New Jersey 07940 USA  
Phone: 800-218-9082 • 973-593-9222  
Fax: 973-593-9277**

**E-mail: [cellis@nac.net](mailto:cellis@nac.net)**

**[www.ellisinstruments.com](http://www.ellisinstruments.com)**

## ISHRS Members Urged to Join the AMA

On behalf of the ISHRS Board of Governors, I urge you to consider joining the American Medical Association (AMA). I realize that the AMA has not been the most popular medical society since its tacit approval of Obama Care, but the fact of life is that it is the most influential medical organization in the world, and when it speaks, all of the State Medical Boards listen.

In 2006, the ISHRS became a member of the American Medical Association’s Specialty and Service Society (SSS), which is a caucus of the AMA’s House of Delegates (HOD). In 2009, the ISHRS was given a seat in the AMA House of Delegates (HOD), which is the largest representative democratic organization in the world with 647 voting members.

The ISHRS’s participation in the AMA HOD speaks to our physician peers that our specialty has arrived, and provides our members the opportunity to have a voice in developing the medical profession’s position on important policy issues as the definitions of our scope of practice, marketing professional ethics, and physician and patient responsibilities within the Doctor-Patient relationship.

In order to retain our voice in the House of Delegates, at least 50% of our U.S. members who are eligible to join the AMA must do so. If you are an AMA member, please renew your membership. If given the option, please indicate your specialty or society affiliation (ISHRS). If you have not joined, then I urge you to do so, to help the ISHRS continue to represent your best interests in the House of Medicine.

Your prompt action is appreciated: <https://commerce.ama-assn.org/membership/>

Sincerely,

Carlos J. Puig, DO, FISHS, ISHRS Delegate to the AMA House of Delegates,  
Immediate Past President, ISHRS



Your AMA membership includes:	How this benefits you:
The JAMA Network (with free JAMA print subscription, savings on 9 specialty journals print subscriptions)	AMA members receive full access to The JAMA Network online, plus the new JAMA Network Reader—a new web app designed to work on any tablet or smartphone. The JAMA Network brings together JAMA and 9 specialty journals to offer fully integrated access to the research, reviews, and perspectives shaping the future of medicine ( <b>valued at more than \$250</b> ).
Expert support through CPT® Network	<ul style="list-style-type: none"> <li>• Free Knowledge Base access to more than 5,000 commonly asked coding questions and answers (\$250 value).</li> <li>• Six complimentary coding inquiries to help you understand and properly use CPT codes and conventions.</li> <li>• Plus, download free CPT® E/M Quick Reference App at the AMA iTunes store.</li> </ul>
AMA model physician employment agreements	The AMA offers members detailed Hospital and Group Model Employment Agreements to walk you through negotiating a contract(s) before entering a group or hospital setting ( <b>valued at \$149 each</b> ).
AMA Physician Profiles sent free upon request	As a member, obtain unlimited complimentary profiles for licensing boards for licensure application/reapplication ( <b>\$37 value per profile</b> ).
New payment model resources	Learn how to evaluate your options and negotiate new payment and delivery models with AMA resources, including webinars, live sessions and presentations.
Help shape AMA policy	Through online forums or live meetings, members weigh in on key issues facing medicine.
A nationwide network of colleagues	Participate in member groups and sections including the Organized Medical Staff Section, Minority Affairs Section and Women Physicians Section.
AMA Insurance savings	Save up to 40% on AMA Insurance products and financial services designed exclusively for physicians.
Member Value Program	Member savings available in AMA's Member Value Program from Mercedes-Benz, Hyatt, UPS®, Wells Fargo®, Henry Schein®, Reputation.com™, HP®, Hertz® and other providers.
AMPAC Political Education Programs	AMA members are eligible to apply for and attend AMPAC's Campaign School and Candidate Workshop with their registration and accommodation expenses covered by AMPAC (AMA's Political Action Committee). These programs have trained physicians to be effective advocates for almost 30 years; graduates have been elected to public offices across the country, including the U.S. Congress ( <b>valued at more than \$1,000</b> ).
AMA Store savings	Save up to 25% at the AMA Store on the books you need (many available in e-book format).

## Bio-Enhanced Hair Restoration from front page

doing this research, I found several references to a vasodilator containing nicotinate being able to raise skin oxygen;<sup>3</sup> after experimenting with it, I came to the opinion that there was some possible benefit there. Unfortunately, individual sensitivities to topical vasodilators vary, some patients have no response and other patients flush and get light-headed!

In 2005, Dr. Bill Parsley introduced me to Bill Ehringer, who was at that time a physiology professor at the University of Louisville. Ehringer had developed and patented a liposomal version of adenosine triphosphate (ATP). After much trial and error, Ehringer's team had created a very specific type of liposome that was able to fuse with the cell membrane and deliver the ATP inside the cell.<sup>4</sup> They were interested in what the liposomal ATP would do as an additive to graft holding solutions. I was much more interested in what it would do as a post-operative treatment for the grafts. I reasoned that if it took up to 5 days for grafts to become revascularized, adding ATP during this time may be beneficial to make up for any shortfall in oxygen.

Over the ensuing years, I tried different strengths and formulations of the liposomal ATP as a post-operative spray; I gradually settled into a protocol that worked well for me. Healing seemed to be enhanced, but more importantly, my graft growth "variability curve" seemed to be shifting to the right (i.e., fewer cases of poor growth, better average results, and more "wow" results). I don't think variability can ever be entirely eliminated from hair transplant results because of all the possible factors that can affect growth, but having the patient spray liposomal ATP on their scalp appears to have a significant positive impact. Several colleagues who have adopted our protocol using liposomal ATP have reported the same thing. Reports in the peer reviewed medical literature prove that liposomal ATP has the ability to protect ischemic cells,<sup>5-7</sup> so it is reasonable to suggest that it will benefit ischemic hair follicles.

How we use ATP: the liposomal ATP (available from Energy Delivery Solutions) comes as a concentrated solution that needs to be diluted for clinical usage. As a holding solution additive, we add 1cc concentrated ATP to 100cc of HypoThermosol FRS. For the post-op spray, we add 10cc ATP to 90cc of saline in a spray bottle we give to the patient. We have them spray every 1-2 hours for the first 48 hours (including waking up the first two nights), and then every 3-4 hours thereafter while awake. For the first couple of days, the patients keep their scalp covered with kitchen cellophane to keep the moisture in, similar to a greenhouse (Figure 2).

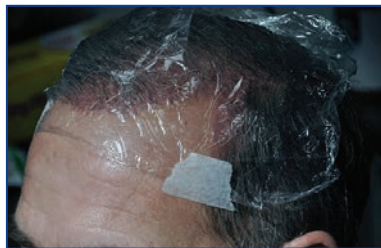

Figure 2. For several days post-operatively, we have our patients wear Saran Wrap over their grafts. This is taped to the forehead and lifted up periodically so the grafts can be sprayed with liposomal ATP.

## Holding Solutions

Going back to Ehringer and Parsley's original interest in ATP as an additive to holding solutions, it seemed to make sense that exogenous ATP would help cells keep functioning while being stored out of body. As a review, graft holding solutions potentially protect grafts from "storage injury" during *ex vivo* storage,

and "ischemia reperfusion injury" if they contain antioxidants.<sup>8</sup> I had come to the conclusion that the potential contribution to graft survival of holding solutions was relatively small compared to graft trauma and ischemia. If the potential benefit was in the range of a 5-10% increase in average graft survival, it would take a well-done, controlled clinical study of at least 50 patients to demonstrate this, something I could not do in my practice.

However, at least when it comes to holding solutions, we have a proxy way of testing their effectiveness. By extending the storage time, we can magnify the difference between various storage solutions and thereby increase the validity of any differences we observe. The assumption here is that if grafts held in storage solution A has drastically superior survival compared to grafts held in storage solution B after 48 hours in storage, then storage solution A probably has some unspecified benefit during the 2-8 hour storage times of a typical hair transplant.

So I tested my favorite holding solution, HypoThermosol FRS, both with and without the addition of the liposomal ATP during an extended storage study. The patient was a 70-year-old man whom I had been taking care of for many years for skin cancer. I had excised a skin cancer on his left temple and had him complete a course of radiation therapy to ensure eradication. This left a large area of complete alopecia in the area. We first excised the donor strip on day one, and dissected the grafts under the microscope per our usual protocol. We then divided the grafts into 3 groups: A) HypoThermosol +liposomal ATP, B) HypoThermosol without ATP, and C) PlasmaLyte A (normal saline pH 7.4), and stored them in these solutions for **5 days** at 4°C. In addition, all of the areas were sprayed post-operatively with liposomal ATP, so the only difference was the storage solution.

The patient was followed periodically and final hair counts and photos were done at 18 months. Graft survival per area was: A) 72%, B) 44%, and C) 0%. HypoThermosol with liposomal ATP was the clear winner (Figure 3). While this study was only of a single patient, it is the longest survival study of hair ever reported (to my knowledge). And it does suggest that there would be some benefit even during shorter storage times (e.g., 2-6 hours) of a standard hair transplant.

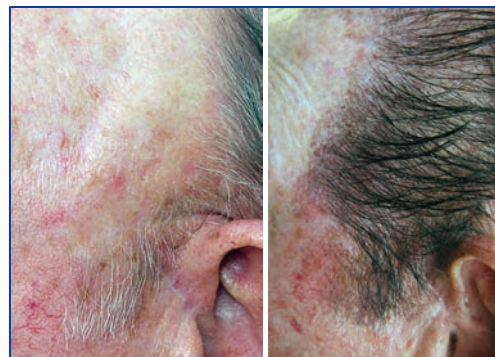

Figure 3. Before (left) and after (right) transplantation with grafts stored for 5 days in HypoThermosol/ATP; over 70% growth was documented by counting hairs, which had been dyed black.

Because I have such faith in HypoThermosol/ATP, I frequently use it for overnight graft storage when needed. For example, if we are doing a large FUE case and do not finish graft placement during a reasonable time, we simply store the grafts in the refrigerator overnight and finish placing the next day (Figure 4). We use tabletop electric chillers (available through Cole Instruments) to ensure grafts are at 4-8°C during the procedure, and,

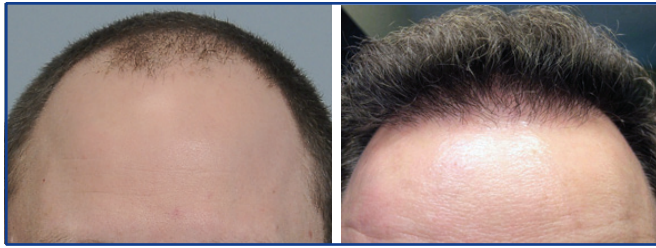

Figure 4. Before (left) and 7.5 months (right) after FUE procedure in which grafts were stored in HypoThermosol/ATP, showing excellent growth.

if necessary, store grafts in a standard refrigerator overnight so they can be placed the next day.

Why choose one holding solution over another? Why HypoThermosol as a graft holding solution, versus another solution such as culture media (e.g., Williams E, DMEM) or IV solution (normal saline, Lactated Ringer's)? When tissue is stored at low temperatures, membrane pumps do not work properly, allowing sodium to rush inside the cell, followed by water. HypoThermosol, which was specifically designed for low temperature storage, prevents this from happening by holding water outside the cell.<sup>9</sup> It also contains glutathione and synthetic vitamin E, which has been proven to prevent ischemia reperfusion injury.<sup>10</sup> Finally, it is in widespread use for cell therapy applications throughout the world.

I have chosen HypoThermosol FRS because I believe it is the most rational choice. I accept that there are no large studies to prove which one is best for hair transplantation, but we can look at what evidence is available and make the best choice in our practice. If we are doing a very large case lasting over 12 hours, or on those rare occasions when we need to store the grafts overnight, I have complete confidence that HypoThermosol FRS is providing the best environment for my grafts.

## ECM

Five years ago, I began experimenting with ACell MatriStem, a commercially available extracellular matrix (ECM) derived from porcine urinary bladder matrix (UBM). Reports continue to appear in the peer reviewed literature confirming the efficacy of UBM for a variety of purposes, such as in muscle regeneration, treating non-healing leg ulcers and as a dressing after skin flap failure.<sup>11-13</sup>

I reviewed my experience with ACell in a previous issue of the *Forum*,<sup>14</sup> where I noted that ACell was useful for the following situations:

1. FUT strip healing: Does not change the appearance of the scar but promotes a softer, more natural feeling result that is easier to re-excise in future procedures (if needed).
2. FUE donor sites: Promotes regeneration if there are any transected follicles remaining in the site, prevents fibrosis, subsequent FUE sessions are easier.
3. Graft coating: Graft growth appears more robust, promotes angiogenesis around graft, and prevents recipient bed fibrosis.

My experience over the last several years has confirmed these observations. ACell is known to activate local stem cells, suggesting a role in helping damaged follicles regenerate. While none of us like to admit that despite our best efforts, some of our grafts are being damaged during placement, it is reassuring to know that grafts coated with ACell have a better chance of regenerating.

I would like to emphasize the "anti-fibrotic" action of ACell because I think it is one of the most important benefits of using this product in hair restoration. When taking a strip out in a patient who has had prior strip surgery, whether ACell was used in the previous surgery is abundantly obvious: the ACell scar is much easier to excise and feels more like virgin scalp, compared to the non-ACell scar, which feels like cutting through a rubber tire. Likewise when doing FUE on someone who has had ACell in their previous FUE, the skin is soft and more like virgin scalp, whereas the non-ACell patient's skin is tougher, and dulls the punch quicker. I would imagine that transection rates are lower as well in patients who have had prior FUE + ACell.

Using ACell-coated grafts helps protect and rejuvenate the recipient bed as well. I have been impressed with ability of ACell to reverse scarring and improve vascularity in scalps that have "old work" (plugs, mini-grafts, etc.) (Figure 5). I believe there is better protection for surrounding pre-existing hair (Figure 6) and that increase vascularity will lead to better growth in future procedures. Dr. David Seager pioneered the "one pass" density result because he believed micro-fibrosis would hinder growth when transplanting into the same area a second time. I believe this is less of a concern when ACell is used.

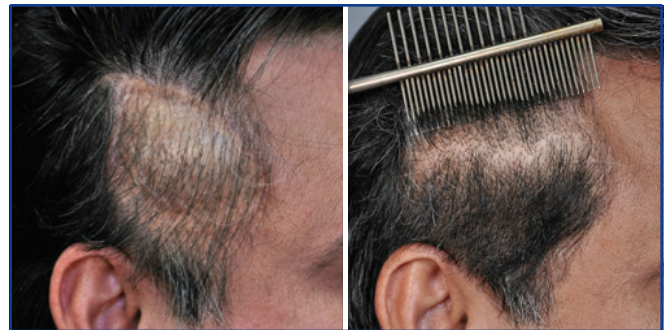

Figure 5. This patient had a skin cancer that was removed and repaired with a graft. A hair transplant at another clinic was not very successful. We transplanted 1,353 FU grafts coated with ACell MatriStem. There is excellent growth and an improvement in the underlying skin texture.

Following is how we use ACell in our office:

1. FUT donor: We take a 3x7cm sheet and cut it length wise into strips, and place these deep in the wound bed and suture the skin over it (Figure 7).
2. FUE donor: We inject PRP+ ACell into the donor area after harvesting, as well as placing some topically, and cover it with kitchen cellophane overnight.
3. Grafts: We create a concentrated suspension by adding a small amount of saline to the powder; a half a drop of this suspension is added to a pile of grafts on the placer's finger prior to placing (Figure 8).
4. Treatment for miniaturizing hair: PRP+ ACell. We add 50-75mg of ACell to our platelet rich plasma (PRP) prior to injection. If done at the same time as the transplant, we inject the PRP/ ACell after the sites are made and before the grafts are placed.

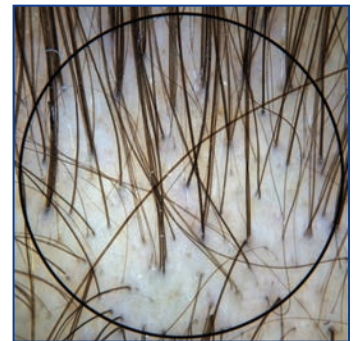


Figure 6. Close-up photograph of an area of scalp where ACell-coated grafts were planted. The grafts can be seen surrounded by pre-existing native hair. Without ACell, these finer hairs may disappear due to fibrosis and loss of vascularity.



Bio-Enhanced Hair Restoration *from page 129*

Regarding this latter application, we have been doing more and more of these procedures in the last couple years. Several reports have appeared in the peer reviewed literature reporting improvements in hair following PRP,<sup>15-16</sup> which adds to Greco's original clinical observations.<sup>17</sup>

My clinical impression is that we can usually achieve mild to moderate thickening beginning at 6 months and maturing at 12 months (similar to a transplant). While the results can vary, it seems that the greater the percentage of miniaturizing hairs, the greater the chance for improvement. When patients ask me how long the benefits last, I answer that it depends on two important factors: 1) their underlying genetics (e.g., balding fast vs. balding slow), and 2) what hair treatments they are on (e.g., results last longer if patient is on finasteride and minoxidil). There is much we do not know about this procedure but the combined experience of those of us doing PRP as a thickening treatment for AGA suggests it is useful and here to stay.

### Conclusion

We currently use liposomal ATP, ACell, and HypoThermosol on virtually every case. We only use PRP/ACell when there is a significant amount of miniaturized native hair. I'm convinced that not only does each product contribute significantly to the final result, but that they are synergistic with each other as well. For example, the growth factors in ACell signal specific cellular actions that require ATP, hence the synergy with liposomal ATP. Over the past 10 years, I have gone through periods where I have used none of these, all of these, or varying combinations; my results are best when I use all three.

Some will question whether all of this is really necessary. I can merely state that these bio-enhancements have helped me improve my results. It is up to each individual surgeon to identify possible areas for improvement in their own results and to make a plan to address these. I'm reminded of the debates in the mid-1990s about whether microscopic dissection was really necessary. Many of us thought this was unnecessary at the time, but individual and collective experience over the years confirmed the superiority of the follicular unit approach. Time will tell whether these bio-enhancements are accepted in the same way. What happens will be determined by our shared clinical experience.

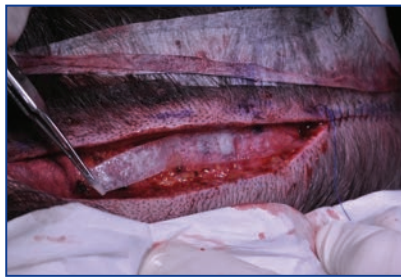

Figure 7. During donor closure, thin strips of ACell sheet are placed deep in the wound bed and the skin is sutured over it.

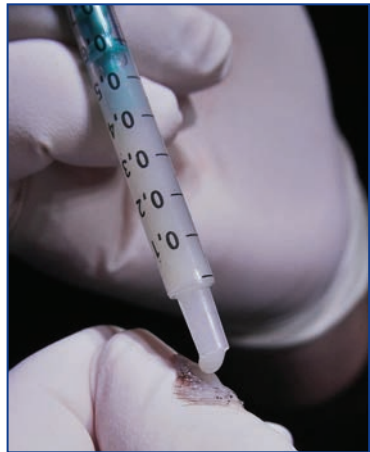

Figure 8. A drop of super-concentrated ACell suspension is placed on a pile of grafts prior to placement.

### References

1. Cooley, J.E. Scalp oxygen levels. Presented at the International Society of Hair Restoration Surgery Annual Scientific Meeting. Las Vegas, 2007.
2. Gordillo, G.M., et al. Evidence-based recommendations for the use of topical oxygen therapy in the treatment of lower extremity wounds. *Int J Low Extrem Wounds*. 2009(Jun); 8(2):105-111.
3. Abramović, Z., et al. Influence of nanosized delivery systems with benzyl nicotinate and penetration enhancers on skin oxygenation. *Int J Pharm*. 2008(Jul); 359(1-2):220-227.
4. Chien, S. Intracellular ATP delivery using highly fusogenic liposomes. *Methods Mol Biol*. 2010; 605:377-391.
5. Atchison, N., et al. Maintenance of ischemic beta cell viability through delivery of lipids and ATP by targeted liposomes. *Biomater Sci*. 2014(Apr); 2(4): 548-559.
6. Korb, V., et al. Current data on ATP-containing liposomes and potential prospects to enhance cellular energy status for hepatic applications. *Crit Rev Ther Drug Carrier Syst*. 2008; 25(4):305-345.
7. Hartner, W.C., et al. ATP loaded liposomes for treatment of myocardial ischemia. *Nanomed Nanobiotechnol*. 2009(Sep-Oct); 1(5):530-539.
8. Cooley, J.E. Ischemia-reperfusion injury and graft storage solutions. *Hair Transplant Forum Int'l*. 2004; 14(4).
9. Mathew, A. A review of cellular biopreservation considerations during hair transplantation. *Hair Transplant Forum Int'l*. 2013(Jan); 23(1):1, 7-11.
10. Ostrowska, A., et al. Hypothermic storage of isolated human hepatocytes: a comparison between University of Wisconsin solution and a hypothermosol platform. *Arch Toxicol*. 2009(May); 83(5):493-502.
11. Sicari, B.M., et al. An acellular biologic scaffold promotes skeletal muscle formation in mice and humans with volumetric muscle loss. *Sci Transl Med*. 2014(Apr); 6(234):234ra58.
12. Lecheminant, J., et al. Porcine urinary bladder matrix: a retrospective study and establishment of protocol. *J Wound Care*. 2012(Oct); 21(10):476, 478-80, 482.
13. Kruper, G.J., et al. Salvage of failed local and regional flaps with porcine urinary bladder extracellular matrix aided tissue regeneration. *Case Rep Otolaryngol*. 2013; 2013:917183. Epub 2013 Sep 26.
14. Cooley, J.E. Use of porcine urinary bladder matrix in hair restoration surgery applications. *Hair Transplant Forum Int'l*. 2011; 21(3):65, 71-72.
15. Cervelli, V., et al. The effect of autologous activated platelet rich plasma (AA-PRP) injection on pattern hair loss: clinical and histomorphometric evaluation. *Biomed Res Int*. 2014; 2014:760709.
16. Park, K.Y., et al. Letter: Platelet-rich plasma for treating male pattern baldness. *Dermatol Surg*. 2012(Dec); 38(12):2042-2044.
17. Greco, J., and R. Brandt. The effects of autologous platelet rich plasma and various growth factors on non-transplanted miniaturized hair. *Hair Transplant Forum Int'l*. 2009; 19(2):49-50. ♦