President's Message

Ken Washenik, MD, PhD, FISHRS | *Beverly Hills, California, USA* | washenik@bosley.com

Greetings Hair Restoration Colleagues,

As we continue to advocate for surgery to be performed by surgeons and practitioners licensed to practice surgery only, I am pleased to share our new "Stand Proud, Be Loud" campaign. Please read more in the notice below. This campaign is an important expansion of the initiative we began at last year's World Congress by distributing the "Where Surgeons Perform the Surgery" buttons, shown below, to our members. I look forward to seeing you in Prague and Poland for ISHRS's Jubilee World Congress and World Live Surgery Workshop. ■

Stand Proud, Be Loud

ISHRS members commit to integrity of profession.

An increasing number of unlicensed personnel worldwide are performing substantial surgical aspects of hair restoration surgery and, in doing so, are putting patients at risk. The ISHRS is committed to the highest standards of medical practice and to educating consumers about this unlawful practice and to following due diligence when researching a hair restoration surgeon.

During the 25th World Congress, ISHRS leaders are asking all members worldwide to stand proud and be loud:

- Stop by the registration table to pick up a badge—and wear it!
- Take a picture of you wearing the badge and post it on Twitter and Facebook. Use the hashtag: #SurgeonsNotTechsPerformSurgery
- Sign the ISHRS online petition to show your commitment to a society where surgeons, not technicians, perform the surgery.
- Post the badge on your website and link to the ISHRS consumer alert page: http://www.ishrs.org/article/consumer-alert-0
- Please share your stories about patients who are seeking ISHRS physician help, asking them to correct mistakes of individuals who are not properly licensed or trained to perform surgical hair transplantation. Send to: info@ishrs.org
- Report any concerns about unlawful practices you see or hear about to your local authorities, states attorney generals, and ministries of health and medical boards.

Co-editors' Messages

Andreas M. Finner, MD
Berlin, Germany
forumeditors@ishrs.org

Bradley R. Wolf, MD, FISHRS
Cincinnati, Ohio, USA
forumeditors@ishrs.org

I'd like to thank all my colleagues who contributed to this issue. The "Controversies" column and a letter to the editor address the growing popularity of FUE. It has been a great achievement and constant effort of the ISHRS to integrate different techniques including FUE and FUT harvesting methods into our curriculum and teaching programs. While some members are not familiar with FUE, many FUE-only surgeons do not know that a well-done strip scar can be very small because they mostly see a subset of patients complaining of a widened scar. The combination of choosing the right patients and taking the strip from the laxest area within the safe donor zone, with adjustment of strip width, trichophytic closure, and avoiding postoperative stretching, can produce minimal scars.

Jae Hyun Park's cover article demonstrates a method to assess scalp elasticity as a major factor influencing scar width. It would be interesting to collect further data in different skin types. During hair transplantation, we often use our tactile senses. After all, good hand-eye coordination is what makes the surgeon successful. Up to now, no machine can replace these manual skills.

Each of us has her or his little tricks. Stretching the skin is often helpful. For stretching, Kuldeep Saxena introduces a spreader device, which he also uses to open the recipient sites. Roberto Vieira describes how to use bent needles to create the recipient sites. While bent needles have been used before, the immediate stick-and-place combination with a dull needle implanter is an interesting technique. Other surgeons prefer to separate the steps of recipient site creation and placing because they leave the preexisting hair a little longer as an orientation when creating sites. Many surgeons like to create all recipient sites before placing. To facilitate placing, they then cut those preexisting hairs a little shorter if the patient allows or even trim them, especially in FUE. The article from the laboratory of Walter Krugluger demonstrates a culture method to study cell-based therapies. Hair cells have tremendous potential as demonstrated by the wound healing study by Francisco Jimenez. Together with our patients we are hoping for further achievements.

Don't hesitate to send in your articles if you have something interesting to report. The World Live Surgery Workshop in Poland and 25th World Congress in Prague offer additional opportunities to share our ideas. See you there. ■

Andreas has put together an interesting and eclectic mix of articles for this issue. It's been almost two years since an article discussing strip excision has graced the cover of our *Forum*. It's good to see Jae Hyun Park's article addressing donor strip scar width. Learning to make narrow scars is the most important aspect of FUT since wide strip scars contributed to the popularity of FUE. Donor math shows that FUE inflicts 4-5× as much scarring as a well-executed strip removal that creates a 1mm wide scar. Knowing how much we can safely remove is very important. Regardless of the technique, FUT or FUE, the donor area is a nonrenewable resource that must be protected, not exploited.

Walter Krugluger, et al. present an interesting article that gives us an update with respect to hair follicle tissue engineering using a three-dimensional, semi-solid culture system. Some terms may sound like a foreign language but this is the language of the future with which we should become familiar as it may shape the future of our specialty. Kuldeep Saxena introduces his interesting spreader and Roberto Vieira describes his new approach with dull needle implanters. No tool, motor, or contraption ensures quality results. The person holding the tool determines the result. And thanks to all the columnists who tirelessly contribute to each issue.

To inculcate implies persistent or repeated efforts to impress on the mind and to teach by frequent repetitions or admonitions. If you are presenting in Prague and your intent is to inculcate fellow hair movers, a 7- or 10-minute lecture given once is unlikely to satisfy the above definition. Please consider submitting your lecture or study as an article to the *Forum* either before or after the meeting. You can reach a broader audience through print. There may be time to publish it in the September/October issue if you submit it shortly after you read these words, if not, there is plenty of time to include it in future issues, so please consider contributing to the *Forum*.

And now Prague, that magical and mystical city. The fame of the "crossroads of the medieval world" spread along the great highways and rivers of Europe and fired the imagination of generations of poets, peasants, artists, philosophers, and alchemists. The architecture of this fairytale city, dominated by a great castle, ancient pinnacles, and spires of gold-filled churches, captures a mysterious mystical quality rarely encountered in the world today (see http://academysacred-geometry.com/courses/alchemy-prague-2016). Last week, the European Commission released its first ever edition of the "Cultural Creative Cities Monitor" that reflects how well culture and creativity help cities thrive. Of 168 cities in 30 European countries, Prague ranks #3 behind only Paris (#1) and Munich (#2), with Milan and Brussels in fourth and fifth place, respectively. Bring your cameras to Prague. ■

Notes from the Editor Emeritus, 2005–07

Francisco Jimenez, MD, FISHRS | *Canary Islands, Spain* | jimenez@clinicadelpelo.com

Hair Transplant Surgeon or…Wound Healing Surgeon?

While the original works in the field of hair transplantation by Shoji Okuda published in 1939 have never been surpassed, the same can be said in the field of wound healing about the work published in 1945 by Bishop, a neuroanatomist from Washington University in St. Louis.[1] By self-inflicting cutaneous wounds on his own forearm at different depths and observing the clinical and histological healing process, Bishop demonstrated that the remaining hair follicles left in the wound bed played a pivotal role in wound healing. Specifically, he demonstrated that 1) reepithelialization of the wound starts not only from the marginal epithelium but also from the remaining hair follicles; and 2) when the skin is destroyed down to the reticular layer, the granulation tissue regenerates most readily from the connective tissue surrounding the hair follicles. This granulation tissue is necessary for migration of the epithelial cells and subsequent healing of the wound surface.

More recent data concerning the cell and molecular pathways involved in the wound healing process have been generated in mouse models, and while important to understand basic principles, their translation to human wound healing remains uncertain. For instance, rodents have two additional confounding factors when attempting a comparison with human wounds: 1) the abundance of hair follicles and lack of eccrine sweat glands in most mouse skin is in stark contrast with most human skin sites, which have an opposite pattern of lack of terminal hairs and abundance of eccrine sweat glands (in human skin the ratio is 3 eccrine glands per 1 pilosebaceous unit),[2] and 2) rodent wounds heal largely by contraction because their skin is loosely attached to the fascia, as compared to the much more tightly attached human skin.

With a view to translating the theoretical healing potential of hair follicles into clinical practice, I decided a few years ago to perform a pilot clinical trial, in conjunction with a group of researchers and physicians from Hospital Donostia in San Sebastian (Spain), with the goal of evaluating the feasibility and safety of transplanting scalp hair punch grafts into the wound bed of chronic leg ulcers.[3] A total of 10 patients with chronic leg ulcers of venous, pressure, and mixed etiology were included. Average ulcer duration was 10.5 years. Within each ulcer, we randomly assigned an experimental area and a control area, both of 4cm^2. Only the experimental area was transplanted with 2mm punch grafts harvested from the scalp and containing mainly terminal hair follicles. At 18 weeks, we observed a significant (27.1%) reduction in the experimental area compared with the control area (6.5%). In addition, we noted in the majority of patients an increase of granulation tissue, ulcer border reactivation, and a decrease of wound exudation.

Given these promising results, I then became involved in a randomized controlled trial to compare the healing capacity of hair follicle scalp punch grafts with punch grafts of the same size but harvested from areas with no visible hairs. Twelve eligible patients with chronic venous leg ulcers were enrolled in the study, which was recently published in the *Journal of the American Academy of Dermatology*.[4] Each patient had one leg ulcer that was divided longitudinally into two halves. One half received 2mm punch grafts from the scalp into recipient sites created with a 14g needle, and the other half received punch grafts from abdominal skin with no visible hairs. The total area of the ulcer and the area of each half transplanted with hairy and non-hairy grafts were measured weekly. At the 18-week end point, a 75.15% ulcer area reduction was observed in the area transplanted with hairy scalp punches compared with 33.7% in the area transplanted with non-hairy grafts, demonstrating that hair follicle punch grafts induced a better healing response. In all patients, we observed a greater decrease in pain and again a greater development of granulation tissue and wound border reactivation in the hair grafted area in comparison with the area transplanted with non-hairy grafts.

After our pilot study, a few other clinical groups have also attempted grafting hair scalp punches in ulcers with similar results. Fox et al., from the University of Miami, reported a patient with a chronic venous leg ulcer refractory to standard treatment and compared the healing potential of hairy and non-hairy grafts.[5] The ulcer in this patient was divided into three segments: one segment was transplanted with scalp punch grafts (6.7cm^2), a second segment received punch grafts harvested from the back (6.9cm^2), and another area served as a control area (7.4cm^2) in which incisions were made with the same needle used to make the recipient sites but without graft transplantation. At week 6, the area that had significantly healed better was the one transplanted with scalp hair punch grafts (91% area reduction). Liu et al. published a study with a total of 14 patients with chronic wounds non-responsive to conventional treatment that were transplanted with follicular unit grafts harvested from the scalp.[6] The epidermis of the follicular units was removed from the graft in order to exclude the possibility that the healing effect was due to non-follicular tissue. They observed complete healing in all patients after 2 months. However, as this study was not randomized and there was no control

➢ PAGE 138

CONTINUED FROM PAGE 137

group, it is difficult to compare results. The same group of surgeons published another retrospective study comparing the clinical outcomes of patients with traumatic or surgical chronic wounds following scalp punch grafts (20 patients) and split-thickness skin grafts (20 patients).[7] They concluded that the ulcers treated with hair follicle grafting achieved better skin/scar quality (more elastic and less contracted) and overall better clinical outcomes than the ulcers treated with split-thickness skin grafts. They observed clinical epithelialization at week 2, significant wound reduction over the first 8 weeks, and total healing in all patients at week 12.

It is also interesting to note that, both in our studies as well as in those of Liu and Yang, in the ulcers treated with scalp hair grafts, the hair shafts grew in far less quantity than would be expected in a normal hair transplant procedure performed in a patient with androgenetic alopecia. This would seem to suggest that the wound microenvironment dictates the fate of the transplanted hair follicles in the direction of wound healing and not in the direction of hair shaft production, a hypothesis suggested earlier by Jahoda in 2001.[8]

While I believe most readers will agree with the assertion that the hair follicle is a potent wound healing promoter, it is puzzling that the application of hair follicle grafts in clinical practice has been so scarce, especially given the enormous cost to health services of treating chronic ulcers and difficult-to-heal wounds and the fact that any hair transplant surgeon can readily perform this procedure using the same surgical tools as in any hair transplant procedure.[9]

My experience as a "wound healing surgeon," although limited by the number of patients treated since I work exclusively in private practice and this technique is obviously more suitable for a Wound Healing Unit in a hospital setting, has been very rewarding. I hope that other colleagues reading these lines become interested in reproducing this technique in difficult-to-heal wounds. Of course, as in any new clinical application, a lot of parameters need to be optimized and several questions need to be addressed, but it is a technique worth trying and I will be happy to collaborate with any clinician who wishes to put it into practice.

References

1. Bishop, G.H. Regeneration after experimental removal of skin in man. *Am J Anat.* 1945; 76:153-181.
2. Rittié, L., et al. Eccrine sweat glands are major contributors to reepithelialization of human wounds. *Am J Pathol.* 2013; 182:163-171.
3. Jimenez, F., et al. A pilot clinical study of hair grafting in chronic leg ulcers. *Wound Repair Regen.* 2012; 20:806-814.
4. Martínez-Martínez, M.L., et al. Hair follicle–containing punch grafts accelerate chronic ulcer healing: a randomized controlled trial. *J Am Acad Dermatol.* 2016; 75:1007-1014.
5. Fox, J.D., et al. Optimizing skin grafting using hair-derived skin grafts: the healing potential of hair follicle pluripotent stem cells. *Wounds.* 2016; 28:99-101.
6. Liu, J.Q., et al. Hair follicle units promote re-epithelialization in chronic cutaneous wounds: a clinical case series study. *Exp Ther Med.* 2015; 10:25-30.
7. Yang, Z., et al. Comparison between hair follicles and split-thickness skin grafts in cutaneous wound repair. *Int J Clin Exp Dem.* 2015; 8:15822-15827.
8. Jimenez, F., et al. Reflections on how wound healing-promoting effects of the hair follicle can be translated into clinical practice. *Exp Dermatol.* 2015; 24:91-94.
9. Jahoda, C.A.B., and A.J. Reynolds. Hair follicle dermal sheath cells: unsung participants in wound healing. *Lancet.* 2001; 358:1445-1448. ■

CONTINUED FROM FRONT PAGE

viewed. All male patients suffered from male pattern baldness. Among the women, 31 patients underwent hairline correction surgery and 3 had female pattern hair loss. Patients with incisions shorter than 15cm in length or with a history of previous hair transplantation surgery, any type of trauma or surgery of the occiput, or face-lift surgery were excluded from the study.

Measurements of laxity, elasticity, and glidability were taken at the time of surgery and compared with scar width measured 10 months after surgery at the following three points: the mid-occipital point and the two mastoid process points lying 5-6cm to the right and left off center.

Measurement of scalp laxity, elasticity, and glidability

The Laxometer II was used to measure scalp laxity. Upward laxity was evaluated for more precise measurements.

While measuring elasticity, the following method was used to limit movement of the dermis: two points separated by 5-6cm were pressed perpendicularly to prevent movement of the dermis over the pericranium. Next, the examiner placed a finger between the two points being compressed and made a small, vertical mark on the fingernail at a point parallel to a millimeter mark on a ruler. The examiner gently pressed the scalp and moved the finger from side to side to stretch the skin. The extent of movement to the right and left was measured. During this stretching, the examiner was careful not to move the fingers compressing and fixing the galea at the two outer points.

The elasticity value was subtracted from the laxity value to calculate glidability (Figure 1).

FIGURE 1. Measurement of scalp elasticity

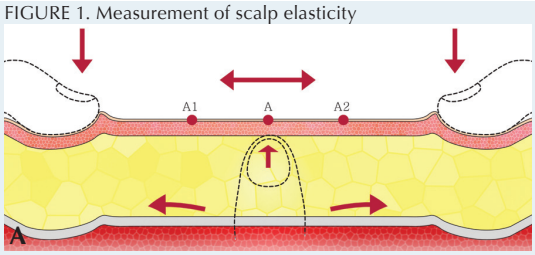

A: Concept diagram

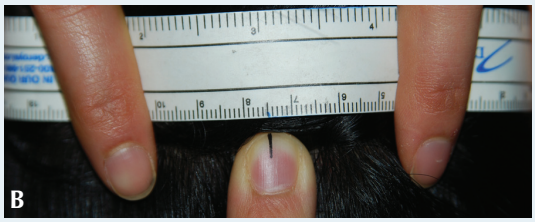

B: Initially, two points 5-6cm apart are compressed perpendicularly to fix the dermis.

C: A fingernail gently makes a vertical mark on the left side.

D: A fingernail gently makes a vertical mark on the right side.

Operative technique

In all patients, 3-0 or 4-0 absorbable vicryl suture was used for galea plication after strip harvesting, followed by a continuous running skin suture with 3-0 or 4-0 nylon. Sutures were removed 10 days after surgery.

RESULTS

Among the 88 patients, the average laxity was 19.59mm (range, 10-30mm), the average elasticity was 8.95mm (range, 4-24mm), and the average glidability was 10.58mm (range, 4-19mm). The average scar width was 2.7mm (range, 1-8mm) at the center, 3.18mm (range, 1-10mm) on the left side, and 3.11mm (range, 1-8mm) on the right side.

Differences in scar width according to elasticity category

Elasticity was categorized as the upper 30th percentile (10mm or more) versus others (less than 10mm) to investigate differences in scar width according to the elasticity group (Table 1).

TABLE 1. Difference in scar width according to elasticity

	Elasticity	*N*	Mean width (mm)	Standard deviation	*t*	*p*
Center	10 mm or more	27	3.48	1.2821	4.364	.000***
	less than 10mm	61	2.38	1.0027		
Left side	10 mm or more	27	3.70	1.6828	2.425	.017*
	less than 10mm	61	2.96	1.1413		
Right side	10 mm or more	27	3.63	1.3053	2.849	.005**
	less than 10mm	61	2.88	1.0535		

*$p < .05$ **$p < .01$ ***$p < .001$

Test results revealed a significant difference in scar width in the two elasticity groups at the center ($t = 4.364$, $p < .001$), on the left side ($t = 2.425$, $p < .05$), and on the right side ($t = 2.849$, $p < .01$).

According to subgroup analysis, the group with an elasticity of 10mm or more had a higher average scar width at the center (3.48mm) than the group with an elasticity of less than 10mm (2.38mm). The scar width on the left side was greater (3.7mm) among those with elasticity of 10mm or more than among those with an elasticity of less than 10mm (2.96mm). On the right side, the average value was also higher for those with an elasticity of 10mm or more (3.63mm) than for those with an elasticity of less than 10mm (2.88mm).

In particular, the group with an elasticity of less than 10mm had only 2 patients out of 61 (3.3%) with scar widths of 4mm or wider, whereas the group with an elasticity of 10mm or more had 13 patients out of 27 (48%) with scar widths of 4mm or wider. Of the 13 patients with wide scars, 1 had a scar 10mm wide at the center and at the left mastoid area and 8mm wide at the right mastoid area; the scars of the remaining 12 patients were 4-5mm in width.

Correlations between variables

Pearson correlation analysis was conducted to define the relationships between variables, the results of which are shown in Table 2.

Scar width and its subdivisions (center, left side, and right

PAGE 140

➤ CONTINUED FROM PAGE 139

TABLE 2. Correlations between variables

		Scar	Center	Left side	Right side	Laxity	Elasticity	Glidability	Incision width	Incision length
Scar width	*r*	1								
	p									
Center	*r*	.920	1							
	p	.000***								
Left side	*r*	.946	.806	1						
	p	.000***	.000***							
Right side	*r*	.922	.765	.816	1					
	p	.000***	.000***	.000***						
Laxity	*r*	.312	.335	.267	.270	1				
	p	.003**	.001**	.012*	.011*					
Elasticity	*r*	.257	.332	.163	.231	.758	1			
	p	.016*	.002**	.128	.030*	.000***				
Glidability	*r*	.079	.009	.153	.047	.385	−.304	1		
	p	.465	.934	.154	.667	.000***	.004**			
Incision width	r	.102	.139	.065	.085	.615	.479	.213	1	
	p	.347	.199	.550	.435	.000***	.000***	.048*		
Incision length	r	.224	.222	.202	.202	.435	.369	.128	.503	1
	p	.037*	.039*	.060	.061	.000***	.000***	.239	.000***	

*$p < .05$; **$p < .01$; ***$p < .001$

side width) share the same factors, and thus had a significant positive correlation. A significant positive correlation also existed between scar width and laxity ($r = .312$, $p < .01$), elasticity ($r = .257$, $p < .05$), and incision length ($r = .224$, $p < .05$).

Relationship between scalp elasticity and scar width after strip harvesting

There was a significant association between elasticity and scar width ($t = 2.465$, $p < .05$). The positive value of the unstandardized coefficient indicates that elasticity has a positive correlation with scar width; that is, the greater the scalp elasticity, the wider the scar after strip harvesting.

DISCUSSION

Accurate assessment of scalp laxity is extremely important to surgeons performing hair transplantation, and laxity should be measured accurately during consultations for surgical planning. In many cases, large numbers of grafts are transplanted in a single session, so the importance of accurate measurement of scalp laxity and its components, elasticity and glidability, cannot be overemphasized.

The purpose of this study was to evaluate the clinical importance of this novel method of measuring scalp laxity, elasticity, and glidability and to assess the relationship between elasticity and donor scar width.

Our method allowed measurement of elasticity without much difficulty, unlike in the past when there was no simple way to clinically measure elasticity.

Based on this study, scalp scar width appears to be influenced by scalp laxity and scalp elasticity. Defining hyperelastic skin as scalp elasticity in the upper 30th percentile, patients with hyperelastic skin had scar widening at all three measurement points. In patients with hyperelastic scalp skin, trichophytic closure or scar revision would not prevent scar widening, leaving patients and surgeons with disappointing results. Therefore, it is imperative to inform patients about the laxity paradox, which can easily occur if elasticity is 10mm or higher. The follicular unit extraction method can be considered in patients who are more susceptible to wider donor strip scars. Also in such cases, trichophytic closure is not always recommended. Conversely, in scalps with greater glidability and lower elasticity, the strip method is expected to leave narrow scars.

According to this study, as components of laxity, elasticity constitutes 45% and glidability constitutes 55%. However, this proportion has interpersonal variations. Because the difference in this proportion serves as a major factor in predicting clinical outcome, preoperative measurement is very important.

Further evaluation and discussion is necessary regarding techniques to prevent donor scar widening in patients with hyperelastic skin undergoing strip surgery. Because of the different characteristics of scalp skin according to race, additional research with different racial populations is also required.

CONCLUSION

Scalp laxity, elasticity, and glidability have great clinical importance in strip method hair transplantation. The present novel method of measuring elasticity helps predict the degree of donor site scar widening.

References

1. Seery, G.E. Surgical anatomy of the scalp. *Dermatol Surg.* 2002; 28:581-587.
2. Bernstein, R.M., and W.R. Rassman. The scalp laxity paradox. *Hair Transplant Forum Int'l.* 2002; 12(1):9-10.
3. Wong, J. Managing wide donor strips. In: W. Unger, et al., Editors. *Hair Transplantation,* 5th edition. London: Informa Healthcare; 2011. pp. 274-276.
4. Feldman, C.S. Tissue laxity based on donor tissue ballooning. *Hair Transplant Forum Int'l.* 2001; 11:119.
5. Mayer, M.L. Evaluation of scalp elasticity. In: W. Unger, et al., Editors. *Hair Transplantation,* 5th edition. London: Informa Healthcare; 2011. p. 267-270.
6. Mohebi, P. How to assess scalp laxity. *Hair Transplant Forum Int'l.* 2008; 18(5):161-167.
7. Mohebi, P. The Laxometer: increasing the safety of hair transplants that use a large number of grafts. *Hair Transplant Forum Int'l.* 2012; 22(6):226-227.
8. Tangjaturonrusamee, C., et al. A new tool to maximize donor harvesting with safer closure. *Dermatol Surg.* 2015; 41:1038-1042. doi: 10.1097/DSS.0000000000000454.
9. Park, J.H. How to use the Laxometer. *Hair Transplant Forum Int'l.* 2013; 23(6):208-209. ■